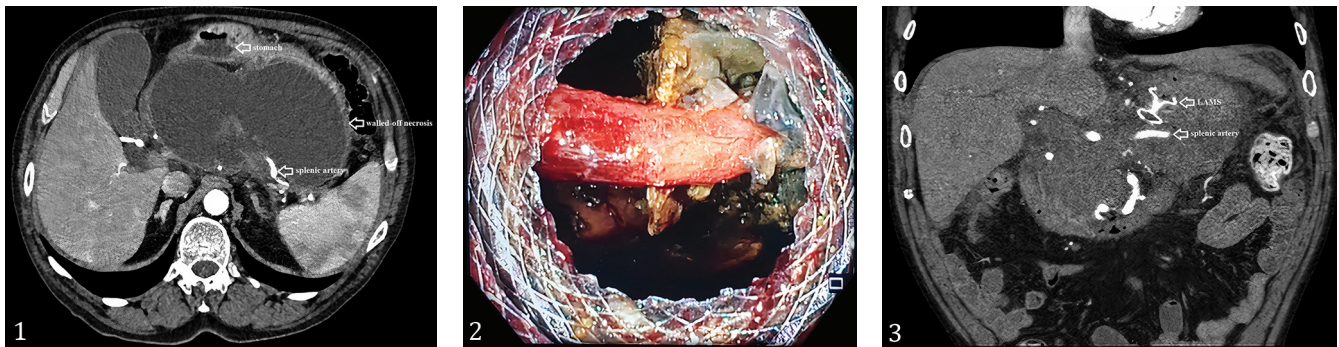


Splenic Artery Revealed after Walled-off Pancreatic Necrosis Drainage: An Uninvited Guest

Pedro Bernardes Antunes, Tânia Carvalho, João Bruno Soares, Bruno Moreira Gonçalves

Gastroenterology Department, Hospital de Braga, Portugal



A 74-year-old male, former smoker, had a recent necrotizing acute pancreatitis. During follow-up he developed abdominal discomfort and early satiety, with twenty percent weight loss. He underwent a computed tomography (CT) four months after the acute pancreatitis; a pancreatic collection of 16x10cm suggestive of walled-off necrosis was identified (Fig. 1) and was proposed for endoscopic ultrasound-guided drainage. By trans-gastric access, in the lesser curvature of the gastric body, a 15x10mm lumen-apposing metal stent (LAMS; Hot AXIOS™, Boston Scientific, MA, USA) was placed with instant fluid output, and its lumen dilated with a 15mm through-the-scope balloon. The collection's interior was then assessed through the LAMS and a tubular and pulsatile structure traversing the cavity, adjacent to the stent's distal flange, was observed (Fig. 2). The patient was admitted for surveillance and underwent a CT angiography, which concluded that the vessel seen on endoscopy was the splenic artery (Fig. 3). Due to a major bleeding risk, the case was discussed with the interventional radiology team for a possible intravascular embolization attempt, but because of the long-term risks associated with splenic infarction, this was left for an emergent scenario only. After 3 weeks, with symptom relief achieved and no main intercurrents registered during hospitalization, LAMS was removed and two double-pigtail plastic stents 10Fr x 3cm were placed in the cavity, with effective drainage. Patient remained asymptomatic and regained weight.

This case illustrates one of the major risks associated with LAMS usage in pancreatic collections' treatment, namely bleeding [1]. Despite the safety of ultrasound-guided procedure, late vascular injury during collection's collapse is possible (ranging from 10.2% to 25%), the splenic artery pseudoaneurysm being the most described cause [2-4].

Imaging mapping and well-timed stent withdrawal is essential for the best outcome, as new endoscopic techniques try to overcome this problem [5].

Corresponding author: Pedro Bernardes Antunes
pedro.m.antunes@hospitaldebraga.min-saude.pt

Conflicts of interest: None to declare.

REFERENCES

- Rinninella E, Kunda R, Dollhopf M, et al. Larghi A. EUS-guided drainage of pancreatic fluid collections using a novel lumen-apposing metal stent on an electrocautery-enhanced delivery system: a large retrospective study (with video). *Gastrointest Endosc* 2015;82:1039-1046. doi:[10.1016/j.gie.2015.04.006](https://doi.org/10.1016/j.gie.2015.04.006)
- Bang JY, Hasan M, Navaneethan U, Hawes R, Varadarajulu S. Lumen-apposing metal stents (LAMS) for pancreatic fluid collection (PFC) drainage: may not be business as usual. *Gut* 2017;66:2054-2056. doi:[10.1136/gutjnl-2016-312812](https://doi.org/10.1136/gutjnl-2016-312812)
- Lang GD, Fritz C, Bhat T, et al. DK. EUS-guided drainage of peripancreatic fluid collections with lumen-apposing metal stents and plastic double-pigtail stents: comparison of efficacy and adverse event rates. *Gastrointest Endosc* 2018;87:150-157. doi:[10.1016/j.gie.2017.06.029](https://doi.org/10.1016/j.gie.2017.06.029)
- Rossi G, Capurso G, Petrone MC, et al. Does co-axial plastic double pig tail stent placement into lumenapposing metal stents reduce risks in EUS-guided drainage of pancreatic fluid collections. *Endoscopy* 2019;51:S59-S60. doi:[10.1055/s-0039-1681345](https://doi.org/10.1055/s-0039-1681345)
- Aslam S, Ansari Z, Alani M, Srinivasan I, Chuang KY. Coaxial double-pigtail stent placement: a simple solution to decrease bleeding risk associated with lumen-apposing metal stent? *Cureus* 2021;13:e1598. doi:[10.7759/cureus.15981](https://doi.org/10.7759/cureus.15981)