

A Modified “Rendezvous” Technique for EUS-guided Recanalization of a Rectal Anastomotic Stricture without Fluoroscopy and Stenting

Dimitrios Kypraios¹, Eleni Manthopoulou¹, Dimitrios Dimitroulopoulos¹, Aris Plastiras², Alexandros Ioannou¹, Dimitrios Katsinelos¹, Klisthenis Tsamakidis¹

1) Department of Gastroenterology, St. Savvas Oncology Hospital of Athens, Athens;
2) Department of Surgery, St. Savvas Oncology Hospital of Athens, Athens, Greece

Address for correspondence:
Eleni Manthopoulou
Department of Gastroenterology, St. Savvas Oncology Hospital of Athens, Leoforos Aleksandras 171, 11522, Athens, Greece
manthopoulouelena@gmail.com

ABSTRACT

Various endoscopic techniques have been described for the treatment of post-operative colonic strictures. Our aim is to report a solely EUS-guided recanalization procedure for a complete rectal stricture, without the use of fluoroscopy or stenting. A 66-year-old male was submitted to low anterior resection and protective ileostomy for rectal adenocarcinoma, complicated with complete anastomotic stricture 6 months later. The patient was treated with a modified EUS-guided rendezvous technique. A colonoscope was advanced through the ileostomy to the sigmoid colon, which was subsequently filled with water. A linear echoendoscope was advanced transanally to the distal part of the rectal anastomosis. The proximal colon was punctured with a 19G needle and a guidewire was advanced through the needle. The rectocolonic fistula tract was first dilated by graduated dilation catheters. Subsequently, progressive pneumatic dilatation was performed. There were no post-procedural complications. At 6-month follow-up the anastomosis was patent, with no significant stricture recurrence. In conclusion, a rendezvous technique for EUS-guided recanalization of complete rectal anastomotic strictures is feasible and safe in a non-radiology assisted setting. In selected cases of distal stenoses balloon dilation could effectively serve as the sole treatment, without the adjunct of stent placement.

Key words: EUS-guided rendezvous – postoperative obstruction – rectal cancer.

Abbreviations: EUS: endoscopic ultrasound; LAMS: lumen-apposing metal stent; SEMS: self-expandable metal stent.

INTRODUCTION

Benign strictures arise in up to 20% of colorectal anastomoses [1]. Endoscopic dilation with or without stent placement have a long-proven efficacy; however, in the case of complete luminal obstruction surgical intervention is usually indicated [2]. Over the years various endoscopic techniques have been developed to avoid invasive surgery. Fluoroscopy assisted endoscopic ultrasound (EUS)-guided recanalization and EUS-guided rendezvous techniques using stents have been described. Our aim is to report the treatment of a complete postoperative rectal stricture by a solely EUS-based

intervention, without using stent or repeated balloon dilations to maintain the lumen patency.

CASE REPORT

A 66 year-old-male with no prior medical history was diagnosed with rectal adenocarcinoma during screening colonoscopy. Pre-operative work-up was negative for lymph nodes or distant metastases and the patient was directly submitted to low anterior resection and protective ileostomy, with no prior chemo- or radio-therapy. Pathologic staging revealed a T1N1M0 carcinoma and adjuvant chemotherapy with capecitabine plus oxaliplatin was administered. Post-operative endoscopic surveillance prior to ileostomy reversal revealed complete luminal obstruction at the site of the anastomosis, 5 cm from the anal verge (Fig. 1). The patient was treated with a combined antegrade endoscopy-assisted and retrograde EUS-guided technique, in a modified “rendezvous” manner. A colonoscope was advanced through the ileostomy to the sigmoid colon and a linear echoendoscope was advanced transanally to the distal part of the rectal anastomosis. The

Received: 27.05.2021
Accepted: 16.07.2021

proximal colon was filled with sterile water, providing an acoustic interface as a target for safe transtenotic puncture with a 19-gauge needle under EUS guidance (Fig. 2). A 0.035" guidewire was advanced through the needle (Fig. 3), visualized endoscopically in the proximal colon. The rectocolonic fistula tract was first dilated by graduated dilation catheters (5-10 Fr). Subsequently, progressive dilatation was performed with controlled radial expansion balloon dilators up to 18 mm diameter (Fig. 4), in a single session. After conventional balloon dilatation, the endoscope easily passed through the anastomosis without any patient discomfort.

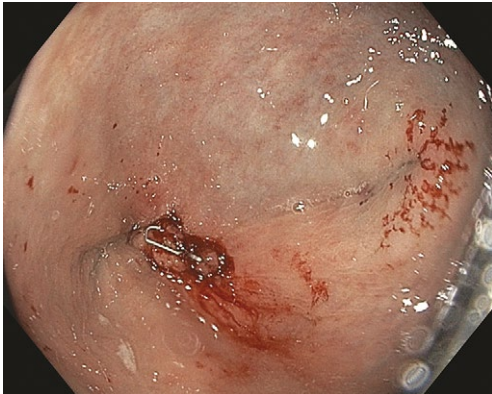


Fig. 1. Endoscopic view of distal rectal stricture.

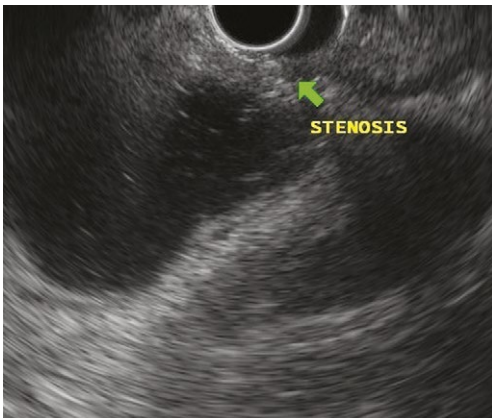

Fig. 2. EUS image of the stricture and the distended, water filled, proximal colon.

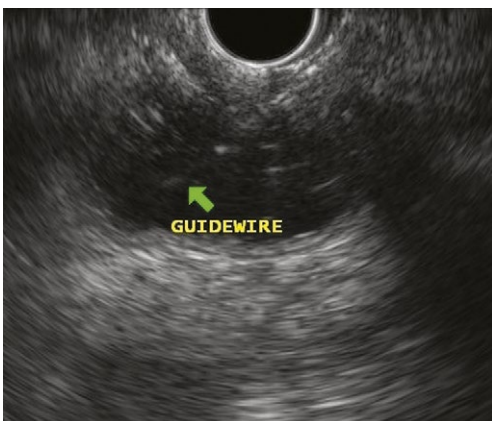


Fig. 3. EUS image of the guidewire advanced to the proximal colon.

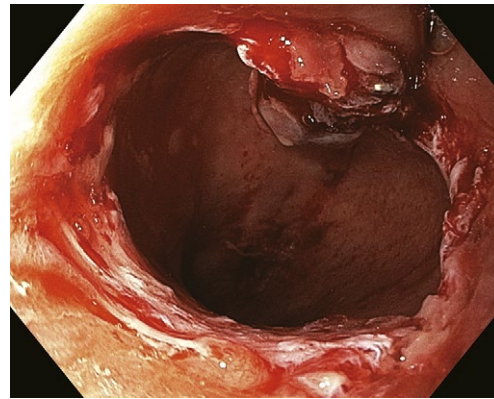


Fig. 4. View of the anastomosis after balloon dilation

Biopsy specimens were obtained. No post-procedural complications occurred and the patient was discharged 24 hours later, instructed for scheduled follow up at 2, 4, 12 and 24 weeks. Biopsies revealed fibrous tissue, with no signs of residual cancer. A month later, the intestinal lumen was patent and the ileostomy was surgically reversed. During the 6-month follow up the patient reported normal bowel habits. On endoscopy, no significant stricture recurrence was noted requiring repeat intervention, i.e. balloon dilation, other than mild lumen calibration by digital palpation.

DISCUSSION

Several non-surgical techniques have been described for complete postoperative rectal strictures, including direct "blind" endoscopic dissection followed by balloon dilation [3] and computed tomography – guided endoscopic recanalization [4]. Despite good results, these methods either increase the risk of wall injury adjacent to the obstruction, or require repeated endoscopic dilations for proper resolution of the stenosis. Preliminary outcomes of EUS-guided techniques seem safe and effective in this field [5], mainly performed with fluoroscopic assistance and supplementary placement of a covered self-expandable metal stent (SEMS) or lumen-apposing metal stent (LAMS) to maintain lumen patency and minimize the risk of perforation [6-8]. In cases of an existing prophylactic ileostomy, antegrade advancement of an endoscope via the stoma to the proximal part of the stricture enables water-filling of the sigmoid and safer EUS-guided puncture of the distal part, in a rendezvous manner [9, 10].

In our case a modified rendezvous technique was applied, since the colonoscope could not reach the exact site of the stricture. Despite that, thorough instillation of water and changing the patient's position allowed for adequate lumen distention and created a safe path to advance the needle and guidewire upstream; this was documented both by endosonography and endoscopy. The ability of EUS to provide detailed control across the stricture minimizes the risk of inadvertent perforation by targeting the exact point of the stenosis without puncturing the normal bowel wall. Simultaneous endoscopic verification of proper guidewire advancement to the proximal colon further eliminates the risk of perforation, possibly rendering fluoroscopic assistance less imperative in similar cases. Thus, a dual benefit could

ensue prevention from unnecessary radiation exposure and simplification of the whole procedure in departments which do not have integrated radiologic equipment available. We did not insert a SEMS or LAMS after the dilation of the stenosis. This decision was primarily driven by the adequate lumen diameter achieved during the procedure, the absence of endoscopic signs of perforation and the proximity to the anal verge (5 cm), which is a risk factor for stent-related complications. Endoscopic dilation has a long-proven efficacy as the sole treatment of colorectal anastomotic strictures [11]; accordingly, our patient required no additional endoscopic intervention during the 6-month follow up, since he presented an adequate lumen caliber efficiently maintained by digital rectal examination. Although stent placement seems prudent in order to ensure long-term clinical success, its role in benign distal rectal strictures is not fully elucidated. No controlled studies exist to demonstrate superiority of stenting over balloon dilation; on the other hand, small retrospective series report a longer duration of lumen patency in patients who received balloon dilation compared to SEMS [12]. Moreover, the risk of stent migration is not negligible, ranging from 8 to 45% for LAMS inserted in the lower gastrointestinal tract for benign strictures [13, 14]. Finally, rare complications such as pain - tenesmus and fecal incontinence are more common when a stent is placed in the distal rectum [15]; this consideration further contributed to a non-stenting approach in our patient.

The patient tolerated the intervention well, with no early or late complications, and a favorable outcome was sustained at 6-month follow-up.

CONCLUSIONS

A rendezvous technique for EUS-guided recanalization of complete rectal anastomotic strictures is feasible and safe in a non-radiology assisted setting. In cases of distal stenoses balloon dilation could effectively serve as the sole treatment, without the adjunct of stent placement.

Conflicts of interest: None to declare.

Authors' contribution: D. Kypraios designed the case report. E.M., A.P., A.I., D. Katsinelos: drafted the manuscript. D. Kypraios, D.D., A.P., K.T. critically revised the case report for important intellectual content. All authors approved the final version of the article.

REFERENCES

- Di Giorgio P, De Luca L, Rivellini G, Sorrentino E, D'amore E, De Luca B. Endoscopic dilation of benign colorectal anastomotic stricture after low anterior resection: A prospective comparison study of two balloon types. *Gastrointest Endosc* 2004;60:347-350. doi:[10.1016/s0016-5107\(04\)01813-9](https://doi.org/10.1016/s0016-5107(04)01813-9)
- Lefevre JH, Bretagnol F, Maggiori L, Ferron M, Alves A, Panis Y. Redo surgery for failed colorectal or coloanal anastomosis: a valuable surgical challenge. *Surgery* 2011;149:65-71. doi:[10.1016/j.surg.2010.03.017](https://doi.org/10.1016/j.surg.2010.03.017)
- Mukai M, Kishima K, Iizuka S, et al. Endoscopic hook knife cutting before balloon dilatation of a severe anastomotic stricture after rectal cancer resection. *Endoscopy* 2009;41 Suppl 2:E193-E194. doi:[10.1055/s-0029-1214776](https://doi.org/10.1055/s-0029-1214776)
- Probst A, Gölder S, Knöpfler E, Axt L, Messmann H. Computed tomography-guided endoscopic recanalization of a completely obstructed rectal anastomosis. *Endoscopy* 2015;47 Suppl 1 UCTN:E32-E33. doi:[10.1055/s-0034-1391131](https://doi.org/10.1055/s-0034-1391131)
- De Lusong MA, Shah JN, Soetikno R, Binmoeller KF. Treatment of a completely obstructed colonic anastomotic stricture by using a prototype forward-array echoendoscope and facilitated by SpyGlass. *Gastrointest Endosc* 2008;68:988-992. doi:[10.1016/j.gie.2008.05.028](https://doi.org/10.1016/j.gie.2008.05.028)
- Artifon EL, Ferreira F, Baracat R, et al. EUS-guided fistulization of postoperative colorectal stenosis in an infant with Hirschsprung's disease: a new technique. *Gastrointest Endosc* 2012;75:459-461. doi:[10.1016/j.gie.2011.03.1241](https://doi.org/10.1016/j.gie.2011.03.1241)
- Martínez-Guillén M, Gornals JB, Consiglieri CF, Castellvi JM, Loras C. EUS-guided recanalization of complete gastrointestinal strictures. *Rev Esp Enferm Dig* 2017;109:643-647. doi:[10.17235/reed.2017.4972/2017](https://doi.org/10.17235/reed.2017.4972/2017)
- Nunes G, Marques PP, Patita M, Allen M, Gargaté L. EUS-guided recanalization of complete colorectal anastomotic stenosis using a lumen-apposing metal stent. *Endosc Ultrasound* 2019;8:211-212. doi:[10.4103/eus.eus_62_18](https://doi.org/10.4103/eus.eus_62_18)
- Saxena P, Azola A, Kumbhari V, Kalloo AN, Khashab MA. EUS-guided rendezvous and reversal of complete rectal anastomotic stenosis after Hartmann's reversal. *Gastrointest Endosc* 2015;81:467-468. doi:[10.1016/j.gie.2014.04.055](https://doi.org/10.1016/j.gie.2014.04.055)
- Poincloux P, Pezet D, Rouquette O. Successful recanalization of complete anastomotic stricture using colorectal endoscopic ultrasound-guided rendezvous thus allowing stoma reversal: two cases. *Endoscopy* 2016;48(S 01):E353-E354. doi:[10.1055/s-0042-118179](https://doi.org/10.1055/s-0042-118179)
- Kim PH, Song HY, Park JH, Kim JH, Na HK, Lee YJ. Safe and Effective Treatment of Colorectal Anastomotic Stricture Using a Well-defined Balloon Dilation Protocol. *J Vasc Interv Radiol* 2012;23:675-680. doi:[10.1016/j.jvir.2011.12.014](https://doi.org/10.1016/j.jvir.2011.12.014)
- Park CH, Yoon JY, Park SJ, et al. Clinical efficacy of endoscopic treatment for benign colorectal stricture: balloon dilatation versus stenting. *Gut Liver* 2015;9:73-79. doi:[10.5009/gnl13326](https://doi.org/10.5009/gnl13326)
- Yang D, Nieto JM, Siddiqui A, et al. Lumen-apposing covered self-expandable metal stents for short benign gastrointestinal strictures: a multicenter study. *Endoscopy* 2017;49:327-333. doi:[10.1055/s-0042-122779](https://doi.org/10.1055/s-0042-122779)
- Bazerbachi F, Heffley JD, Abu Dayyeh BK, et al. Safety and efficacy of coaxial lumen-apposing metal stents in the management of refractory gastrointestinal luminal strictures: a multicenter study. *Endosc Int Open* 2017;5:E861-E867. doi:[10.1055/s-0043-114665](https://doi.org/10.1055/s-0043-114665)
- Han SH, Lee JH. Colonic stent-related complications and their management. *Clin Endosc* 2014;47:415-419. doi:[10.5946/ce.2014.47.5.415](https://doi.org/10.5946/ce.2014.47.5.415)