

## Laparoscopic greater curvature plication - a new and safe bariatric procedure

### To the Editor,

Morbid obesity is affecting an increasing number of people worldwide and when clinical treatment does not achieve the expected results, bariatric surgery becomes the last resource. Laparoscopic greater curvature plication (LGCP) is a new bariatric restrictive procedure that avoids the complications linked with the permanent implant of an adjustable gastric ring (oesophageal laceration, gastric erosion) while also minimizing the possibility of leaks associated with sleeve gastrectomy.

Also known as gastric imbrication and total vertical sleeve plication, the procedure consists of reducing the gastric volume by placing at least two rows of non-absorbable sutures on the greater gastric curvature. Having as forerunners an open technique tried in 1968 [1] and the StomaphyX [2] device used in reducing a large stomach pouch after unsatisfactory bariatric procedures, LGCP was first described in 2007 [3]. Trials were initiated in the USA in 2009 and the first paper was published in 2010 [4]. Our personal experience is limited to 3 cases.

The standard 5 trocar approach starts with the dissection of the angle of His. The greater curvature is dissected with a bipolar forceps leaving the vascular arcade intact. Posterior gastric adhesions have to be freed in order to achieve an adequate mobility. The first row of interrupted extramucosal non-resorbable stitches is calibrated on a 32-40-Fr bougie. The second continuous suture suffices to reduce adequately the gastric volume. No gastric aspiration tube and no dye leakage tests are necessary.

Nausea, vomiting and sialorrhoea may affect up to one third of the patients during the first two weeks [3, 4]. A liquid diet is started as soon as it can be tolerated, gradually switching to solid food after two weeks. Proton

pump inhibitors are recommended for 60 days. Follow-up visits should be scheduled after 1 week, 1, 3, 6, 12 and 18 months.

Although the available data offer only studies on a low number of patients, the results are very good. The mean hospital stay is less than 48 hours, with return to activity in 7 days [4]. The leaks are exceptionally rare [3] and no other complications are yet reported. Another advantage is the low conversion rate to the open procedure.

The loss of excess body weight reaches 20% at 1 month, 32% at 3 months and stabilises at 60% at one year [3, 4], figures comparable to those obtained with other restrictive procedures (adjustable gastric ring, sleeve gastrectomy). The evolution is not affected by weight regain.

Upper endoscopy or barium swallow are not mandatory, unless symptoms of reflux are present. The imbricated gastric fold is smaller at 6 months compared with the evaluation at 1 month and remains unchanged after a longer period. The lumen size appears also unaffected by dilation [4].

Laparoscopic greater curvature plication is a safe and efficient bariatric procedure that prospective trials and a longer follow-up should confirm in order to gain wider acceptance.

Cosmin Puia, Vlad Puia  
3<sup>rd</sup> Surgical Clinic  
UMF "Iuliu Hațieganu"  
Cluj-Napoca, Romania

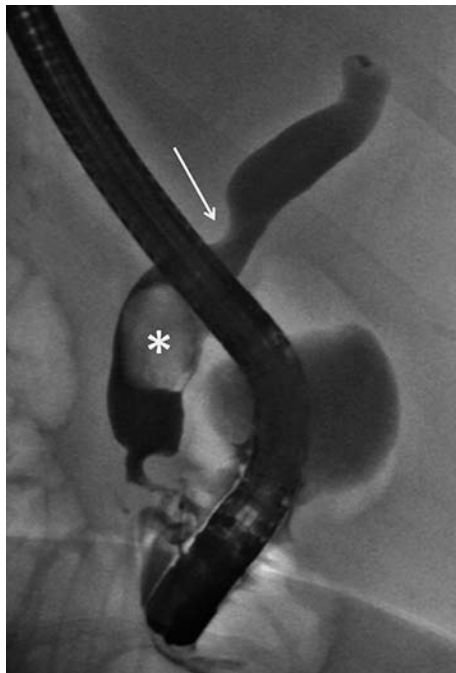
### References

1. Kirk RM. Gastric imbrication as a method of weight control. *Br J Surg* 1968;55: 867.
2. Mikami D, Needleman B, Narula V, Durant J, Melvin WS. Natural orifice surgery: initial US experience utilizing the StomaphyX device to reduce gastric pouches after Roux-en-Y gastric bypass. *Surg Endosc* 2010; 24: 223-228.
3. Talebpour M, Amoli BS. Laparoscopic total gastric vertical plication in morbid obesity. *J Laparoendosc Adv Surg Tech A* 2007;17: 793-798.
4. Ramos A, Galvao Neto M, Galvao M, et al. Laparoscopic greater curvature plication: initial results of an alternative restrictive bariatric procedure. *Obes Surg* 2010;20: 913-918.

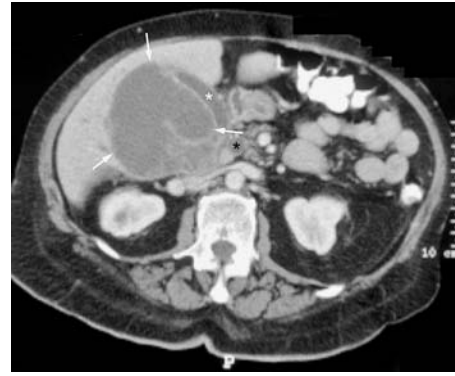## Multiple complicated gallbladder disease

### To the Editor,

A 75-year-old woman was referred from another hospital due to jaundice and suspected gallbladder carcinoma. On admission, the patient was afebrile and reported recurrent pain in the right upper quadrant and weight loss of about 10 kg in three months. Relevant laboratory data included white blood cell count  $24.2 \times 10^9/L$  (normal 4-10), C-reactive protein 158 mg/l ( $< 5$ ), bilirubin 7.8 mg/dl ( $< 1.1$ ), and  $\gamma$ -glutamyltransferase 666 U/l ( $< 40$ ). Abdominal ultrasound showed intra- and extrahepatic bile duct dilation and signs of acute calculous cholecystitis with inhomogeneous wall thickening and an adjacent hypoechoic liver mass. After administration of intravenous antibiotics, endoscopic retrograde cholangiography was performed revealing suppurative cholangitis and multiple common bile duct (CBD) stones. Furthermore, there was a smooth tapering compression in the CBD's middle portion reminiscent of Mirizzi syndrome (Fig. 1). After sphincterotomy, the bile duct was cleared from stones. Abdominal CT revealed an enlarged and wall-enhancing gallbladder with a surrounding fluid collection (Fig. 2). At ultrasound-guided puncture, putrid material was aspirated, and a percutaneous drainage was inserted. Alpha-hemolytic streptococci were isolated, and pathologic evaluation of core biopsies indicated bacterial inflammation, notably, with pronounced plasmacellular and foamy cell infiltration. After further clinical stabilization and removal of the drainage, MRI demonstrated a small



**Fig 1.** Endoscopic retrograde cholangiography: a distal CBD stone (white asterisk) and a smooth compression of the CBD's mid-portion reminiscent of Mirizzi syndrome (arrow).



**Fig 2.** Computed tomography: a thickened and enhancing wall of the enlarged gallbladder (arrows), a dilated CBD (black asterisk) and pericholecystic fluid collection (white asterisk).

gallbladder with persistent contrast uptake of the thickened wall compatible with ongoing inflammation but no clear-cut evidence for malignancy. In anticipation of surgical problems due to adhesions and obscured anatomy, the patient was subjected to an uncomplicated open cholecystectomy with intraoperative frozen-section examination. This and the final pathologic evaluation established the diagnosis of xanthogranulomatous cholecystitis (XGC), accounting for the multiple complicated course including liver involvement with incipient abscess formation, extensive choledocholithiasis causing ascending cholangitis, and incomplete Mirizzi syndrome.

Xanthogranulomatous cholecystitis is a unique variant of cholecystitis with intense fibroproliferative inflammation and distinct pathological characteristics such as foamy cell infiltration and bile-containing xanthogranulomatous nodules [1]. Chronic infection in a setting of cholelithiasis and bile stasis in conjunction with extravasation of bile vesicles into the gallbladder wall through ruptured Rokitansky-Aschoff sinuses are considered key elements in XGC pathogenesis. There is a marked propensity to destructive extension into surrounding tissues and, thus, complicated clinical courses, for instance perforation and fistulous tract or abscess formation [2]. Current data indicate an incidence rate of 2.2 % in symptomatic gallbladder diseases in Great Britain [3]. In the absence of characteristic features on imaging studies, such as intramural nodules or bands, which are lacking in most patients, the clinical diagnosis of XGC is challenging [4]. In our case, XGC was contemplated in the preoperative differential diagnosis most of all due to the suggestive pathological biopsy analysis. However, to complicate things further, there is a significant risk of concurrent gallbladder carcinoma, for which the condition per se is often mistaken. Obstructive jaundice is a common feature in the clinical presentation mainly owing to choledocholithiasis, while Mirizzi syndrome has only anecdotically been reported [3]. Xanthogranulomatous cholecystitis has been associated with failure of laparoscopic cholecystectomy and high conversion rates, although recent data suggest that a laparoscopic approach may be an option for selected patients [5].

Vincent Zimmer<sup>1</sup>, Jochen Raedle<sup>1</sup>,  
Rainer Grobholz<sup>2</sup>, Alexander Massmann<sup>3</sup>,  
Martin K. Schilling<sup>4</sup>, Frank Lammert<sup>1</sup>

1) Department of Medicine II; 2) Institute  
of Pathology; 3) Department of Diagnostic and  
Interventional Radiology; 4) Department of General,  
Visceral, Vascular and Paediatric Surgery, Saarland  
University Hospital, Homburg, Germany

## References

1. Varadarajulu S ZS. Xanthogranulomatous cholecystitis. . UpToDate, Basow, DS (Ed) 2009; UpToDate, Waltham, MA, 2009.
2. Houston JP, Collins MC, Cameron I, Reed MW, Parsons MA, Roberts KM. Xanthogranulomatous cholecystitis. *Br J Surg* 1994; 81:1030-1032.
3. Srinivas GN, Sinha S, Ryley N, Houghton PW. Perfidious gallbladders - a diagnostic dilemma with xanthogranulomatous cholecystitis. *Ann R Coll Surg Engl* 2007;89:168-172.
4. Parra JA, Acinas O, Bueno J, Guezmes A, Fernandez MA, Farinas MC. Xanthogranulomatous cholecystitis: clinical, sonographic, and CT findings in 26 patients. *AJR Am J Roentgenol* 2000;174:979-983.
5. Kwon AH, Matsui Y, Uemura Y. Surgical procedures and histopathologic findings for patients with xanthogranulomatous cholecystitis. *J Am Coll Surg* 2004; 199:204-210.

## Fluindione: a francophone oral anticoagulant drug utilized in liver transplant recipients for Budd-Chiari syndrome

### To the Editor,

Budd-Chiari syndrome (BCS) is characterized by hepatic venous outflow obstruction. The natural history of BCS is still poorly understood [1]. Liver transplantation (LT) in patients with BCS has been shown to be complicated sometimes by recurrent thrombosis along with difficulties in establishing a precise cause for this thrombosis [2, 3]. Anticoagulation with heparin followed by warfarin is considered to be the therapy of choice to prevent post-transplant thrombosis [4]. However, in France there are at least two oral anticoagulant (OA) drugs with widely different properties that can be administered in such patients: warfarin and fluindione. We compared the safety and effectiveness of these drugs in patients who underwent liver transplantation for BCS on a long term follow-up. Between January 1997 and December 2008, 32 patients with BCS underwent LT in two different centres. The diagnosis of BCS was confirmed by imaging studies. All patients underwent liver replacement (piggy-back) using whole grafts. All patients received intravenous heparin sodium 6-8 hours after surgery (total daily dose of 10,000–25,000 U) and were converted to warfarin or fluindione a week later to maintain an international normalized ratio (INR) of 2.2–3.0. Standard immunosuppressant therapy was based on calcineurin inhibitors and steroids. Of these 32 patients, 16 received warfarin (W group) and 16 fluindione (F group) after LT. The choice of the type of OA drug was

based on physician competence and conviction. While no major bleeding complications were identified in the two groups, statistical differences ( $p=0.026$ ) in minor bleeding episodes were reported between the groups (6 in W group and 2 in F group). All bleedings were treated conservatively and no transfusions were required.

Liver transplantation should be considered in patients affected by BCS when other therapies are unsuccessful [2, 3, 5, 6]. However, to the present day many aspects of this complicated disorder have remained in need of clarification. [1, 5]. One of them is the management with OA after LT [1-5]. Currently, an armamentarium of different anticoagulant drugs exists [5-7]. Warfarin is the most preferred and commercialized OA drug worldwide, but in France and other few francophone countries, fluindione is the most frequently used [7-8]. This different utilization remains unexplained. It was for this reason we decided to compare the follow up of these two groups of patients (W vs F) after LT for BCS, focusing on the side-effects of these drugs. As we reported, warfarin or fluindione had similar efficacy in preventing thrombosis in patients with BCS after LT. However, a difference between the groups regarding the minor bleeding episodes was observed. In particular, bleeding was less observed in the F-group. Moreover, less number of dose-adjustments to obtain a targeted INR was required in the F-group. This may be related to a shorter half-life of fluindione with respect to warfarin.

In conclusion, OA treatment with fluindione is a valid option when compared to warfarin and should be considered in patients transplanted for Budd-Chiari syndrome everywhere in the world including francophone countries.

### Disclosure statement

There is no relationship between the authors and the drug companies.

Fabrizio Panaro<sup>1</sup>, Hassan Bouyabrine<sup>1</sup>,  
Majd Hamoui<sup>1</sup>, Philippe Wolf<sup>2</sup>, Francis Navarro<sup>1</sup>

1) Centre de Chirurgie Hépatique et de  
Transplantation, Hôpital St. Eloi, Hôpitaux  
Universitaires de Montpellier, Montpellier; 2) Centre  
de Chirurgie Viscérale et de Transplantation, Hôpital  
de Haute-pierre, Hôpitaux Universitaires de Strasbourg  
- Université Louis Pasteur, Strasbourg, France

## References

1. Rajani R, Melin T, Björnsson E, et al. Budd-Chiari syndrome in Sweden: epidemiology, clinical characteristics and survival - an 18-year experience. *Liver Int* 2009;29:253-259.
2. Ulrich F, Pratschke J, Neumann U, et al. Eighteen years of liver transplantation experience in patients with advanced Budd-Chiari syndrome. *Liver Transpl* 2008;14:144-150.
3. Darwish Murad S, Kamath PS. Liver transplantation for Budd-Chiari syndrome: when is it really necessary? *Liver Transpl* 2008;14:133-135.
4. Kitchens CS, Weidner MH, Lottenberg R. Chronic oral anticoagulant therapy for extrahepatic visceral thrombosis is safe. *J Thromb Thrombolysis* 2007;23:223-228.

5. Klein AS. Management of Budd-Chiari syndrome. *Liver Transpl* 2006;12(11 Suppl 2):S23-S28.
6. Senzolo M, Cholongitas EC, Patch D, Burroughs AK. Update on the classification, assessment of prognosis and therapy of Budd-Chiari syndrome. *Nat Clin Pract Gastroenterol Hepatol* 2005;2:182-190.
7. Mahé I, Grenard AS, Joyeux N, Caulin C, Bergmann JF. Management of oral anticoagulant in clinical practice: a retrospective study of 187 patients. *J Gerontol A Biol Sci Med Sci* 2004;59:1339-1342.
8. Comets E, Pousset F, Mentré F, et al. Prediction of fluindione maintenance dosage hampered by large intraindividual variability. *Ther Drug Monit* 2000;22:668-675.

## Clinical penetrance of C282Y homozygous HFE hemochromatosis in a western Romanian population

### To the Editor,

In 1996, Feder and colleagues showed that homozygosity for C282Y mutation (C282Y/C282Y) in the HFE gene is responsible for the majority of cases of typical phenotypic hereditary hemochromatosis (HH) [1]. Since then, many studies have examined the relationship between HFE genotype and HH phenotype in individual cohorts as well as in cross-sectional population-based samples [2, 3]. Differences in inclusion criteria and in the definition of biochemical and disease penetrance have produced a range of estimates for the penetrance of C282Y homozygosity (1-90%) [4]. No study has estimated the clinical penetrance of C282Y homozygosity in the Romanian population.

We analyzed all cases diagnosed with HH at the Clinic of Gastroenterology and Hepatology, Emergency County Hospital in Timisoara, western Romania, from 2005 to 2009. The diagnosis was established based on the following criteria: absence of secondary causes of iron overload; transferrin saturation (TS) >50% and/or serum ferritin concentration (SF) >300 µg/l and/or serum iron concentration (sFe) >170 µg%; grade III or IV siderosis by Perls stain (grade III, marked iron deposition with coalescent granules; grade IV, massive iron deposition in hepatocytes of the entire lobule). In one patient who refused a liver biopsy, liver iron overload was established by magnetic resonance imaging. The analysis of C282Y mutation was done as described elsewhere [5]. All subjects participating in the study gave their informed consent. Statistical evaluation was performed using the software package SPSS version 15.0 for Windows (SPSS Inc., Chicago, IL).

Of the 6 patients who were diagnosed with HH and underwent HFE genotyping, 2 were homozygous and 1 was heterozygous for C282Y mutation (Table I). The overall mean age of the study group was 51.3±9.2 years (range 39-62). Male to female ratio was 5:1. Age and the values of serum iron markers (TS, SF, sFe) were comparable between C282Y/C282Y homozygotes and patients with other genotypes (C282Y/wild-type or wild-type/wild-type).

The allele frequency of C282Y mutation in the Romanian population is 1.75% (95% CI, 0.7 to 3.7) [6] with an estimate of 1 C282Y/C282Y homozygote in about 3,266 people. The

**Table I.** Characteristics of patients diagnosed with hereditary hemochromatosis

Case	Age (years)/ Gender	Penetrant disease	HFE genotype (C282Y mutation)
1	39/M	SFe = 280 µg% SF = 620 ng/ml Liver biopsy: grade III	C282Y/wt
2	58/M	SFe = 203 µg% SF = 530 ng/ml Liver biopsy: grade III	wt/wt
3	44/M	SFe = 233 µg% SF = 1000 ng/ml Liver biopsy: grade IV	C282Y/C282Y
4	47/M	SFe = 175 µg% SF = 7837 ng/ml Liver biopsy: grade IV	C282Y/C282Y
5	62/F	SFe = 172 µg% SF = 490 ng/ml TS = 59% Liver biopsy: grade III	wt/wt
6	58/M	SFe = 215 µg% SF = 479 ng/ml TS = 91% MRI: liver iron overload	wt/wt

F, female; M, male; MRI, magnetic resonance imaging; SF, serum ferritin; SFe, serum iron concentration; TS, transferrin saturation; wt, wild-type

Emergency County Hospital in Timisoara has a catchment area of 500,000 adult persons from western Romania. Using these data, the expected number of C282Y/C282Y subjects is 153 (95% CI, 152.6 to 153.5). As 2 C282Y/C282Y symptomatic patients were identified in the area, these figures enabled the evaluation of the range of total penetrance of this genotype in the western Romanian population, which was estimated at 1.3% (95% CI, 1.1 to 1.5). Considering the same definition of penetrant disease, similar figures were reported in South Wales, UK (1.2%) [7] and Southern France (2%) [8].

In this study, the large discrepancy between the number of people diagnosed with HH and the estimated number of people homozygous for C282Y is unlikely to be largely explained by under-diagnosis. Extensive meta-analyses of 202 genetic association studies provided evidence of strong associations between C282Y/C282Y and liver disease as well as porphyria cutanea tarda [3]. It seems unlikely that unrecognised disease in patients with porphyria cutanea tarda will explain the large discrepancy that we found.

At present, the burden of disease caused by HH is small in the western Romanian population. Until other genetic and/or environmental co-factors that influence disease expression are understood more fully, we believe that the benefits of C282Y mutation screening in this region, both to the individual and to the community, are likely to be outweighed by the costs.

### Acknowledgements

We are grateful to Simona Bota, M.D. (Emergency County Hospital in Timisoara, Romania) for providing important details about the patients.

Adriana M. Neghina<sup>1</sup>, Andrei Anghel<sup>1</sup>,  
Ioan Sporea<sup>2</sup>, Alina Popescu<sup>2</sup>

1) Department of Biochemistry; 2) Department of  
Gastroenterology-Hepatology  
„Victor Babes” University of Medicine and Pharmacy,  
Timisoara, Romania

## References

1. Feder JN, Gnirke A, Thomas W, et al. A novel MHC class I-like gene is mutated in patients with hereditary haemochromatosis. *Nat Genet* 1996; 13: 399-408.
2. Neghina AM, Anghel A. Hemochromatosis genotypes and risk of iron overload - a meta-analysis. *Ann Epidemiol* 2011; 21: 1-14.
3. Ellervik C, Birgens H, Tybjaerg-Hansen A, Nordestgaard BG. Hemochromatosis genotypes and risk of 31 disease endpoints: meta-analyses including 66,000 cases and 226,000 controls. *Hepatology* 2007; 46: 1071-1080.
4. European Association for the Study of the Liver. EASL clinical practice guidelines for HFE hemochromatosis. *J Hepatol* 2010; 53: 3-22.
5. Neghina AM, Anghel A, Sporea I, et al. Mutant HFE genotype leads to significant iron overload in patients with liver diseases from western Romania. *J Appl Genet* 2009; 50: 173-176.
6. Voicu PM, Cojocariu C, Petrescu-Danila E, Covic M, Stanciu C, Rusu M. Prevalence of HFE (hemochromatosis) gene mutations C282Y and H63D in a Romanian population. *Blood Cells Mol Dis* 2009; 42: 14-15.
7. McCune CA, Al-Jader LN, May A, Hayes SL, Jackson HA, Worwood M. Hereditary haemochromatosis: only 1% of adult HFEC282Y homozygotes in South Wales have a clinical diagnosis of iron overload. *Hum Genet* 2002; 111: 538-543.
8. Aguilar-Martinez P, Bismuth M, Blanc F, et al. The Southern French registry of genetic hemochromatosis: a tool for determining clinical prevalence of the disorder and genotype penetrance. *Haematologica* 2010; 95: 551-556.

## Face to face with Crohn's disease: two cases when infliximab works as the best cosmetics

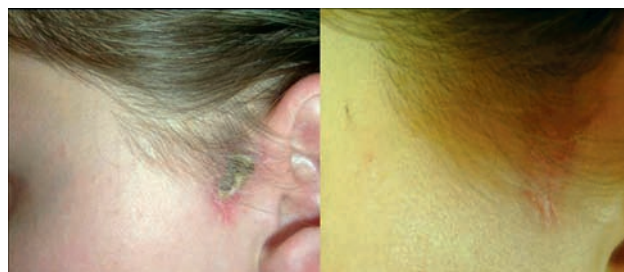### To the Editor,

Metastatic Crohn's disease (CD) located on the face is a rare entity which significantly affects the patients' quality of life and usually does not respond to conventional therapy. We report two cases of metastatic CD involving the nose and the preauricular region that responded well to infliximab therapy.

#### Case 1

A 25-year-old female patient was diagnosed with CD in 2007 when she developed aphthous stomatitis followed by high fever, diarrhea and a painful mass in the preauricular region requiring surgical intervention. In September 2009 she developed perianal fistula. The patient underwent drainage surgery and azathioprine was initiated. In December 2009 the patient presented with a recently activated 2x1 cm discharging preauricular fistula. Although the histology of the lesion did not reveal granuloma, the simultaneous clinical activity of the preauricular fistula and the intestinal symptoms suggested

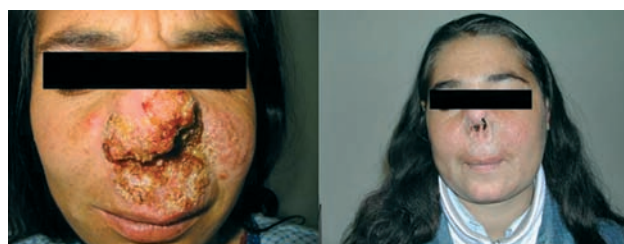the diagnosis of metastatic CD. Because of the simultaneous refractory perianal fistula, biological therapy was initiated after Seton placement. Infliximab induction therapy resulted in a rapid remission of the preauricular lesion (Fig. 1) and the discharge of the perianal fistula also significantly decreased.



**Fig 1.** Metastatic CD affecting the preauricular region before and after infliximab therapy

#### Case 2

A 23-year-old female was admitted to the Dermatology Department with a destructing and exuding nasal scar in March 2003. The histology evaluation of the cutaneous biopsy suggested CD as a background systemic disease. Gastrointestinal examinations did not confirm the diagnosis of CD. However, the histology revision of previous surgical samples performed because of multiple enterocutaneous fistulas revealed CD-specific granulomas. After one year of ineffective treatment with antibiotics and corticosteroids, infliximab was initiated. Six weeks after the second infusion the scar became significantly smaller and the discharge from the nasal lesion ceased. With the use of combined infliximab and azathioprine maintenance therapy, further skin improvement was observed during the follow-up (Fig. 2).



**Fig 2.** Metastatic CD affecting the nasal region before and after infliximab therapy.

Cutaneous extraintestinal manifestations of CD are relatively common (2-44%) [1]. However, metastatic CD is rarely documented on the skin. If it is, it is mainly in the perianal and genital region. It seems that the same inflammatory cells and cytokines are involved in the reactive-type of extraintestinal symptoms of CD by being overexpressed in the extracolonic tissues [2]. Because of the common origin, the same therapeutic intervention is usually effective both in the intestine and in the extraintestinal tissue. Kaufman et al found infliximab to be the most beneficial in the management of mucocutaneous manifestations of CD [3].

Metastatic CD of the face is rarely documented in the literature [4, 5]. Two cases were published regarding the presence of metastatic CD in the retroauricular area [6, 7], while nasal manifestation has been published in 7 patients.

Successful treatment of facial metastatic CD with infliximab was first published in 2006 [6] and confirmed by four additional reports of metastatic CD effectively treated with infliximab. Our case reports represent two unusual manifestations of metastatic CD with a beneficial effect of infliximab in the management of the fistulizing skin diseases. The previous reported cases and our results suggest that TNF- $\alpha$  blockers may be the best therapeutic modalities in such complicated cases.

Klaudia Farkas<sup>1</sup>, Pál Miheller<sup>2</sup>, Zoltán Szepes<sup>1</sup>, Dóra Lippai<sup>2</sup>, Tibor Wittmann<sup>1</sup>, Tamás Molnár<sup>1</sup>  
 1) First Department of Medicine, University of Szeged, Szeged; 2) Second Department of Medicine, Semmelweis University, Budapest, Hungary.

## References

1. Delgado J, Delgado B, Sztarkier I, et al. Presentation of Crohn's disease as metastatic cutaneous non-caseating granulomatous lesions. *Isr Med Assoc J* 2003; 5: 897-898.
2. Das KM. Relationship of extraintestinal involvements in inflammatory bowel disease: new insights into autoimmune pathogenesis. *Dig Dis Sci* 1999; 44: 1-13.
3. Kaufman I, Caspi D, Yeshurun D, Dotan I, Yaron M, Elkayam O. The effect of infliximab on extraintestinal manifestations of Crohn's disease. *Rheumatol Int* 2005; 25: 406-410.
4. Graham DB, Jager DL, Borum ML. Metastatic Crohn's disease of the face. *Dig Dis Sci* 2006; 51: 2062-2063.
5. Chuah JH, Kim DS, Allen C, Hollis L. Metastatic Crohn's disease of the ear. *Int J Otolaryngol* 2009; 2009:871567.
6. McCallum DI, Gray WM. Metastatic Crohn's disease. *Br J Dermatol* 1976; 95: 551-554.

## Perspective on routine rectal retroflexion during screening colonoscopy; a survey of American gastroenterologists

### To the Editor,

Retroflexion in the rectum as part of screening colonoscopy has not consistently shown an increase in adenoma or cancer detection rates [1, 2]. Retroflexion can cause rectal perforation [3] and was not explicitly recommended in the gastroenterological societies guidelines as a quality measure of screening colonoscopy [4, 5]; however it is endorsed by some experts [6] and previous studies [7]. It is unclear what the frequency of rectal retroflexion (RR) use is; therefore we conducted a survey to estimate it and to determine if any factors are associated with such practice.

In November 2009, we surveyed 6960 non-trainee members of the American College of Gastroenterology in North America about their practice of RR in asymptomatic patients during screening colonoscopy. The response rate

was 17% (1184 respondents). We collected information about the location, type of practice and the number of years in practice. Permission to conduct the survey was granted by the Medstar Institutional Review Board.

Among the 1184 respondents, 5 did not answer the question about RR, 22 (2%) did not perform RR and 1157 (98%) performed RR on a regular basis. Among endoscopists who performed RR, the most common reason for performing RR (848 subjects, 75%) was a 'personal preference to avoid missing adenomas and cancers' and the most common reason for avoiding RR (848 subjects, 78%) was a 'narrow rectum'. In the 'free text' section, 27 (2.5%) endoscopists stated that RR should be done on every patient regardless of any possible contraindication. The most common reason among endoscopists who did not perform RR for avoiding the procedure (17 subjects, 81%) was a 'personal experience that it does not increase adenomas or cancers' detection rates (Table I).

**Table I:** Distribution of respondents based on the reasons behind their practice in performing or not routine rectal retroflexion (RR) during screening colonoscopy - multiple answers are possible for each respondent

Reasons for performing RR	N=1132
Based on general recommendations for colorectal cancer screening	300 (26.5%)
Based on published studies on colorectal cancer screening	89 (8%)
Personal preference to avoid missing rectal tumors	848 (75%)
To search systematically for other ano-rectal diseases	591 (52%)
Just by habit or prior training, but not sure about yield	304 (27%)
Reasons for avoiding RR	N=21
Based on general recommendations in colorectal cancer screening	1 (5%)
Based on published studies on colorectal cancer screening	0 (0%)
Personal experience that it does not increase adenoma / cancer detection rates	17 (81%)
Concerns about rectal perforation	11 (52.5%)
Concerns about patient discomfort	6 (28.5%)
No prior training in rectal retroflexion	0 (0%)
Time constraints during the procedure	0 (0%)

On forward viewing, 1063 (94%) missed at least 1 adenoma, and 641 (57%) missed more than 6 adenomas, which could only be seen on retroflexion. Eighty (7%) endoscopists had one rectal perforation and only one respondent had two rectal perforations. Only seniority (duration in practice >15 years), but not location or type of practice, predicted a lower rate of RR use (Table II). The effect of seniority persisted if the cutoff age for seniority is taken at the 10-year mark (juniors 99.4% vs. seniors 97.6%,  $p=0.03$ ), but disappeared if the cutoff age was taken at the 5-year mark ( $p=0.2$ ).

This data shows that RR during screening colonoscopy in asymptomatic patients is an extremely common practice

**Table II.** Number (%) of respondents who perform routine rectal retroflexion (RR) during screening colonoscopy based on their seniority, type and location of practice.

Practice duration	>15 year N=522 (44%)	<15 years N=660 (56%)	P value
Rate of RR	97%	99.6%	0.001
Location	Eastern USA N=645 (63%)	Western USA N=384 (37%)	
Rate of RR	97.7%	98.7%	0.25
Type of practice	Academic N=316 (27%)	Private N=859 (73%)	
Rate of RR	97.5%	98.4%	0.3

among endoscopists in North America. Its use slightly decreases with seniority. Most gastroenterologists believe that RR is a safe procedure with little time constraints that can increase the rate of adenomas and cancer detection. The literature strongly supports the need to examine as much as possible of the colonic mucosa with great care [8]. Intuitively RR may be a maneuver that increases the area inspected in wide rectums and consequently increases adenomas and cancers detection rates [2]. The value of this maneuver may have to be discussed explicitly in future panels for colorectal cancer screening guidelines.

Wissam E Mattar<sup>1</sup>, Anjali S Kumar<sup>2</sup>, Kevin W Olden<sup>1</sup>

1) Division of Gastroenterology and Hepatology, Washington Hospital Center, 2) Section of Colon and Rectal Surgery, Washington Hospital Center, Washington DC, USA

## References

1. Cutler AF, Pop A. Fifteen years later: colonoscopic retroflexion revisited. *Am J Gastroenterol* 1999; 94: 1537-1538
2. Saad A, Rex DK. Routine rectal retroflexion during colonoscopy has a low yield for neoplasia. *World J Gastroenterol* 2008;14:6503-6505
3. Quallick MR, Brown WR. Rectal perforation during colonoscopic retroflexion: a large, prospective experience in an academic center. *Gastrointest Endosc* 2009;69:960-963
4. Davila RE, Rajan E, Baron TH, et al. ASGE guideline: colorectal cancer screening and surveillance. Standards of Practice Committee, American Society for Gastrointestinal Endoscopy. *Gastrointest Endosc* 2006;63:546-557
5. Rex DK, Johnson DA, Anderson JC, et al. American College of Gastroenterology guidelines for colorectal cancer screening 2009. *Am J Gastroenterol* 2009;104:739-750
6. Hanson JM, Atkin WS, Cunliffe WJ, et al. Rectal retroflexion: an essential part of lower gastrointestinal endoscopic examination. *Dis Colon Rectum* 2001; 44: 1706-1708
7. Varadarajulu S, Ramsey WH. Utility of retroflexion in lower gastrointestinal. *J Clin Gastroenterol* 2001;32:235-237
8. Rex DK. Maximizing detection of adenomas and cancers during colonoscopy. *Am J Gastroenterol* 2006;101:2866-2877