

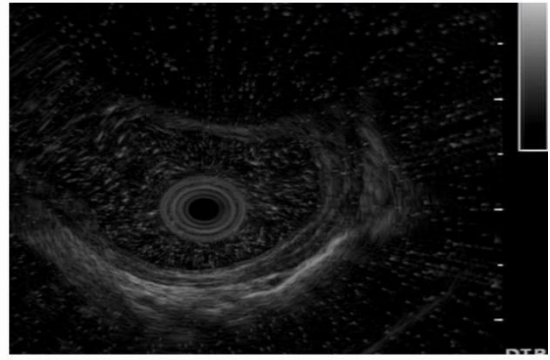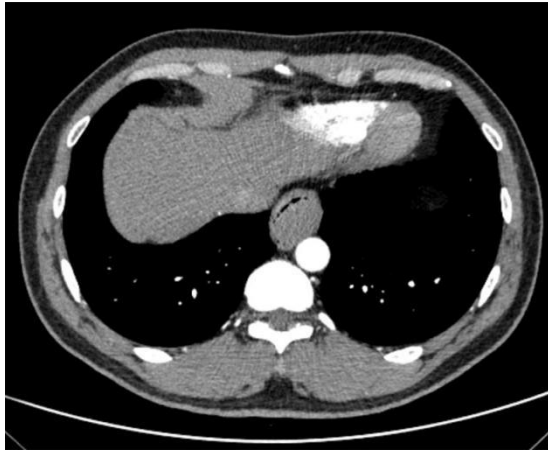Figure S1. The large esophageal tumor originated from the muscularis propria, as shown by endoscopic ultrasound.

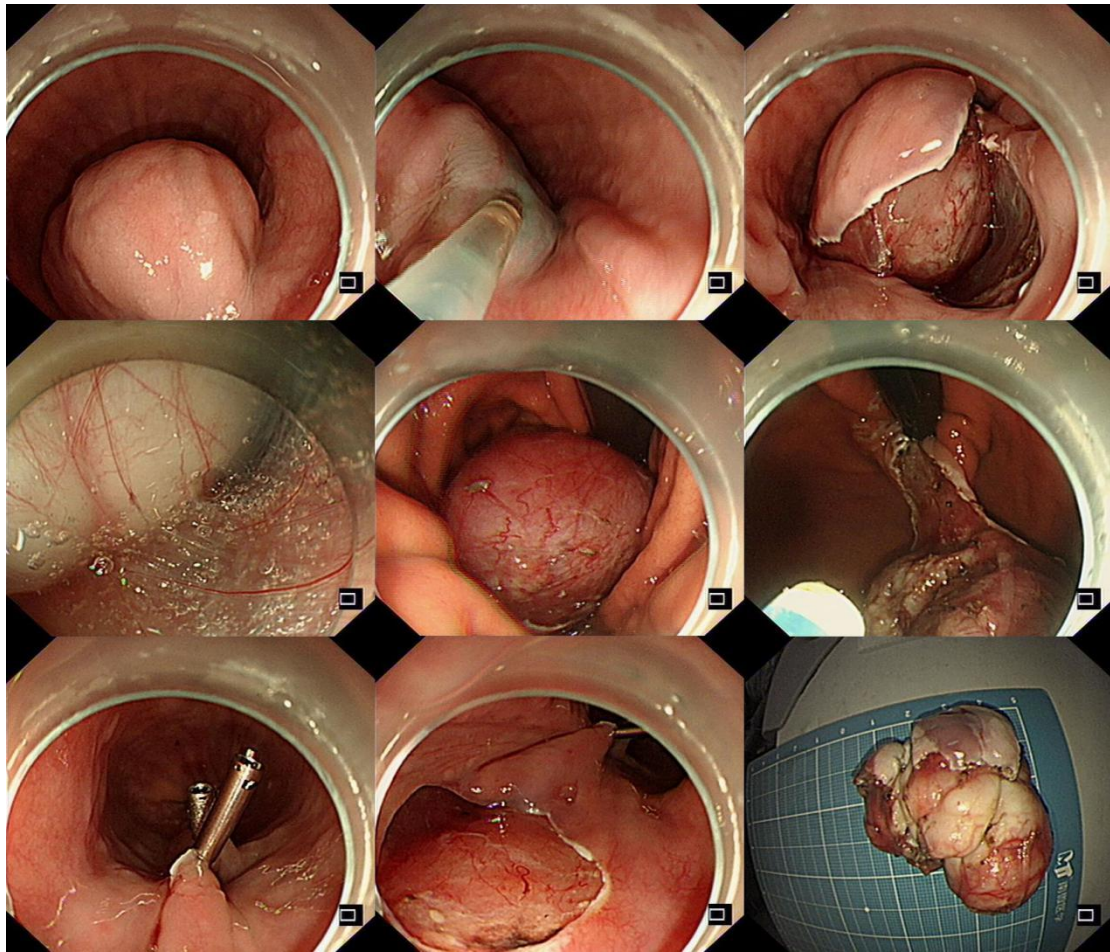


Figure S2. Open dissection and resection of the huge submucosal tumor at the distal end of the esophagus.

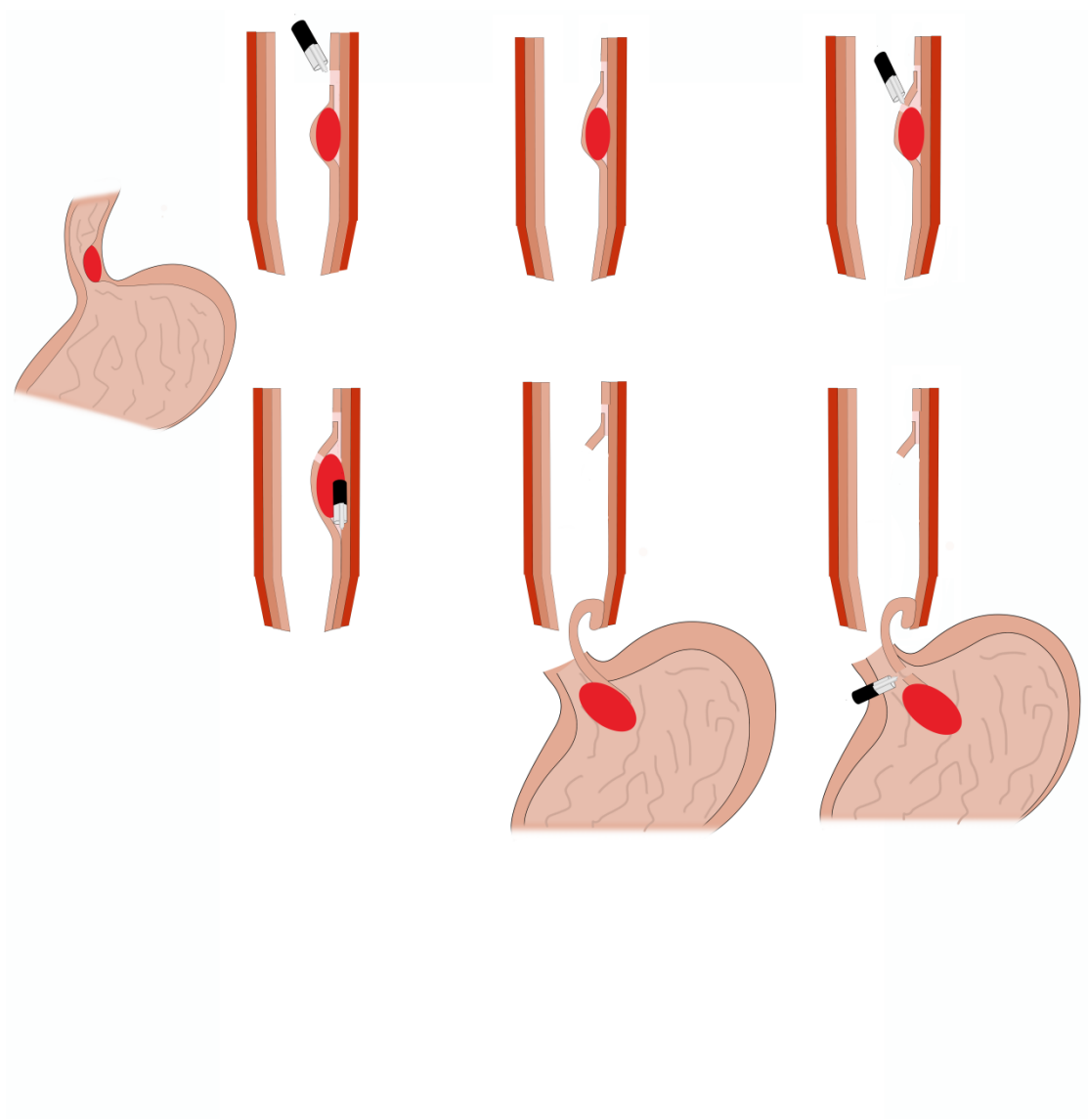


Figure S3. The specific operation process of the modified open submucosal tunnel dissection.