

Herpes Simplex Virus Hepatitis - It's High Time We Consider Empiric Treatment

Udayakumar Navaneethan^{1,2}, Elisha Lancaster¹, Preethi GK Venkatesh², Jiang Wang³, Guy W Neff¹

1) Department of Internal Medicine, University of Cincinnati College of Medicine, Cincinnati; 2) Digestive Disease Institute, The Cleveland Clinic Foundation, Cleveland; 3) Department of Pathology, University of Cincinnati College of Medicine, Cincinnati, USA

Abstract

Fulminant hepatitis is an uncommon complication of herpes simplex virus infection. Patients at risk, in particular pregnant women and immunosuppressed patients presenting with fulminant liver failure, receiving delayed acyclovir intervention may lose significant liver parenchyma prompting the need for liver transplantation. The diagnosis is often not straight forward due to the lack of specific signs or symptoms, while many patients are diagnosed at autopsy. Although herpes simplex virus associated fulminant hepatic failure carries a high mortality risk, early intervention with acyclovir may prove to be life saving. In fact, acyclovir given in the early stages of fulminant hepatic failure may prevent mortality and avoid the need for liver transplantation. We report here two pregnant women with fulminant herpes simplex virus hepatitis in whom a difference of a few hours in the initiation of empiric treatment made a vast difference to their hospital stay. The above results demonstrate a significant impact to fulminant hepatic failure and should prompt clinicians to consider empiric acyclovir therapy for at risk patients.

Key words

Herpes simplex virus – fulminant hepatic failure – acyclovir – pregnancy.

Introduction

Herpes simplex virus (HSV) hepatitis is an uncommon complication of HSV infection [1]. The diagnosis is often delayed due to the lack of specific signs or symptoms. Primary and/or recurrent HSV infection can result in disseminated

infection leading to fulminant hepatic failure (FHF), liver transplantation or death. Although immunocompetent patients can be affected, immunosuppressed patients and pregnant women constitute almost 75% of cases reported thus far with HSV hepatitis [2].

More than 50% of patients with HSV hepatitis are only diagnosed at autopsy [2]. A recent analysis of all the 137 patients suggested that treatment with acyclovir, if instituted early, may reverse disease and avoid the need for liver transplantation [2].

We report here two women with fulminant HSV hepatitis in whom a difference of a few hours in the initiation of the empiric treatment made a vast difference to their hospital stay.

Case 1

A 26 year-old G3P2 female, at 30 weeks gestation presented to an outside hospital with an acute onset of “flu like symptoms.” In the emergency room (ER) she was evaluated with a basic laboratory work up which was normal. The patient was sent home with symptomatic treatment only. Two days later the patient returned to ER with flu like symptoms. Physical examination was normal except for mild splenomegaly. Laboratory evaluation was significant for a platelet count of 101,000/mm³, aspartate aminotransferase (AST) 204 IU/L, alanine aminotransferase (ALT) of 104 IU/L. Her past medical history was only significant for hypothyroidism and her only medications were pre-natal vitamins.

On initial examination at our institution, she was febrile to 102.7°F. Her conjunctiva was non-icteric and skin and examination of the oral/genital mucosa did not show any lesions significant for viral infection. Laboratory examinations showed a white blood count (WBC) of 3000 cells/mm³, hemoglobin of 9.1 g/dl and platelets 73,000/mm³. The liver tests gave rise to concern for rising AST/ALT at 515/269 with a total bilirubin of 0.7 mg/dl. Coagulation work up was normal. Lactate dehydrogenase (LDH) was elevated to 4800 IU/L. The suspicion was for syndrome of hemolysis, elevated liver enzymes, and low platelets

Received: 20.12.2009 Accepted: 30.01.2010

J Gastrointest Liver Dis

March 2011 Vol. 20 No 1, 93-96

Address for correspondence:

Udayakumar Navaneethan M.D.
Digestive Disease Institute
The Cleveland Clinic Foundation
Cleveland, OH 44195, USA
Email: navaneu@ccf.org

(HELLP) or acute fatty liver of pregnancy. The patient was managed supportively. On hospital day (HD) 3, the patient had a rapid clinical deterioration with altered mental status and increasing fetal contractions.

The laboratory examinations were significant for a WBC of 1000/mm³, hemoglobin of 8 g/dl and platelets 55,000/mm³, AST of 7997 IU/L, alanine aminotransferase (ALT) 3010 IU/L, total bilirubin 2.1 mg/dl, alkaline phosphatase of 102 IU/L and prolonged prothrombin time consistent with diagnosis of pancytopenia, coagulopathy, and acute liver failure. The patient was empirically started on I.V. acyclovir and was taken for an emergent C-section with intraoperative liver biopsy.

Postoperatively, the patient received 6 units of fresh frozen plasma (FFP), 6 units platelets, 20 units of cryoprecipitate, 4 units of PRBCs, and 2000 units recombinant factor VIII. All viral hepatitis, cytomegalovirus (CMV) and Epstein - Barr virus (EBV) serologies were negative. Biopsy results confirmed the diagnosis of HSV hepatitis showing 70% necrosis of the liver (Figs. 1, 2). The patient was in hospital for a month before making a complete recovery. Of note, on HD 7 the patient developed a genital lesion consistent with acute HSV infection.

Case 2

The second patient was a 20 year old G2P2 female who presented 2 days after delivering her baby with fever, headache and "flu like symptoms" from an outside hospital. She had complained of some headache, fever and nausea 3 days prior to presentation and developed fetal contractions and delivered the baby. Laboratory examinations at that time were all normal. On HD 3, she had continued fever and a WBC count of 1500 cells/mm³, hemoglobin of 9.4 g/dl and platelets 84,000 cells/mm³ and was transferred to our tertiary care center. On admission, the patient was febrile and had asterixis but the rest of the physical examination was normal. Her admission examinations were significant for pancytopenia with a WBC of 1,100 cells/mm³, hemoglobin of 8.6 g/dl and platelet count of 40,000 cells/mm³, AST of 2346 IU/L, ALT 1908 IU/L, total bilirubin 0.8 mg/dl, AKP of 85 IU/L and elevated PT. The patient was started on I.V. acyclovir empirically immediately after admission. The patient's mental status improved over the next 48 hours. PCR for HSV-1 and 2 both came back positive on the 4th day of hospitalization. The remainder of the hepatitis serologies, CMV and EBV were negative. The patient improved dramatically with normalization of liver function tests and the blood counts within 10 days and was discharged home to complete the 14 days of treatment.

Discussion

The above cases clearly illustrate the varying clinical presentation, and epitomize the difficulty of the diagnosis of HSV in patients presenting with non specific clinical symptoms [3]. HSV-1 infection affects the oral mucosa, while HSV-2 is most commonly associated with genital

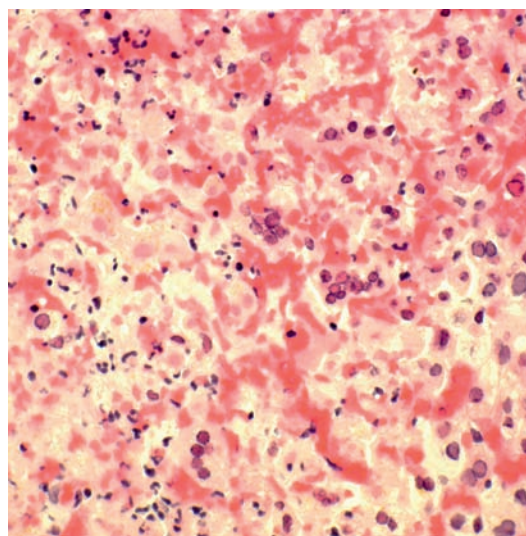


Fig 1. Liver biopsy showing intranuclear viral inclusions within the necrotic areas (H&E, x100).

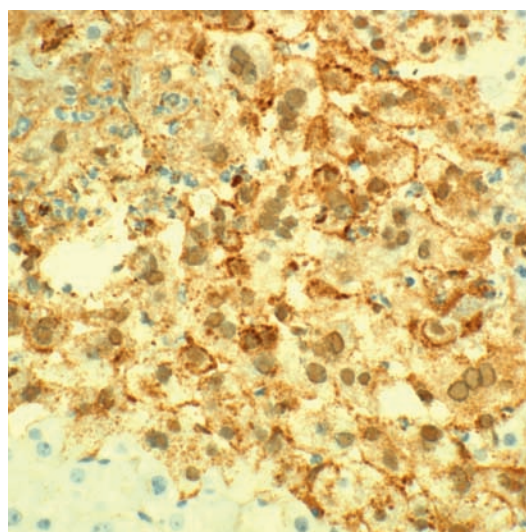


Fig 2. Immunostaining for HSV strongly positive by immunohistochemistry (x100).

lesions. Both can cause FHF, although HSV-2 seems to be more frequent [4], particularly in pregnant women where 63% of the reported cases are due to HSV-2 [4-6]. Fulminant hepatic failure from HSV particularly affects immunocompromised hosts, including pregnant women, patients with solid organ or hematopoietic transplantation [2, 7-10]. Disseminated infection may result either from host factors or viral factors [11].

Pregnant women are particularly susceptible as the immunological changes during pregnancy suppress T-cell-mediated immunity promoting disseminated infection [12]. HSV hepatitis presents typically as anicteric hepatitis with a "transaminitis", associated with typical viral prodromal symptoms, leukopenia, or thrombocytopenia [4]. About 2% of pregnant women acquire HSV and the risk of FHF in these patients is not known [13]. Severe FHF can also result in disseminated intravascular coagulation and renal failure [14].

In the review of all the reported HSV cases, 49 (36.6%) of 134 patients received acyclovir treatment. Patients who received treatment were less likely to die or require liver transplantation (51% vs. 88.1%, $p < 0.001$) compared to untreated patients [2]. In treated patients, the mean time from overt symptoms to treatment with acyclovir was 4.2 ± 1.8 days. There was a delay in the initiation of treatment (mean 4.7 vs. 3.5 days, $p = 0.03$) in patients who died or required liver transplantation as compared to patients who survived [2]. In addition, acyclovir is easy to administer and has few side effects. However, a recent commentary questioned the rationale for use of acyclovir in patients with indeterminate acute liver failure (ALF) as HSV hepatitis constituted only 0.4% of the 1033 consecutive adult ALF patients [15]. In fact, in a study of stored serum from 51 indeterminate ALF patients and 12 pregnancy-related ALF patients, HSV was not detected in any which led to the conclusion that acyclovir should not be used in all indeterminate ALF patients [16].

The review of the current literature and our case report highlights a number of important issues. Hepatitis caused by HSV should be considered strongly in the high risk population even in the absence of classic clinical manifestations, particularly pregnant women and immunocompromised patients who constitute 75% of the cases reported thus far in the literature [2]. Although rare, many case reports in the literature have demonstrated a difficulty in rapid diagnosis resulting in FLF. Kaufman et al showed that only 23% of cases among the 52 HSV hepatitis cases reviewed were diagnosed ante mortem [17]. In fact, in the review of all cases reported in the literature close to 58% of patients were diagnosed only at autopsy. The characteristic rash occurred in less than half of the cases [2].

As this series shows, in the first patient, treatment was started on the third HD (5 days from symptom onset), while the second patient received treatment on the first HD (3 days from symptom onset). Failure to treat early, even a difference of 36-48 hours while awaiting serologic studies, can result in vast differences in the hospital course as demonstrated. Diagnosis is difficult given the lack of specific findings such as herpetic lesions. Additional challenges come from the lack of rapid diagnostic modalities for HSV.

Currently, the major laboratory tests used for diagnosis of HSV are liver biopsy, viral culture, antigen detection tests (enzyme immunoassay or immunofluorescence on smears), and nucleic acid detection with polymerase chain reaction (PCT/RT-PCR) [18, 19]. A review of the current state of testing modalities shows the low utility in guiding early empiric therapy decisions [20].

A recent commentary highlighted that occult HSV infection has no role in indeterminate ALF [15]. We do agree that acyclovir has a minimal role in all patients in FHF. However in patients at risk, pregnant women and immunocompromised patients, empirical treatment should be considered. Acyclovir is classified as a category B drug in pregnancy with no fetal risk demonstrated in animal or human studies. The question of the safety of acyclovir in pregnancy has been reinforced in multiple studies where

the rates of birth defects (2.6%) were not different from the expected rate (3.2%) in the general population [21, 22]. Future studies to evaluate the cost effectiveness of empirical treatment and outcome should be investigated.

To conclude, the above cases clearly illustrate how a delay of a few hours can have an effect on the hospital course. The administration of intravenous acyclovir is inexpensive, without drug interactions, and safe even during pregnancy. The above data suggests an addition to present algorithm to include empiric acyclovir therapy for FHF patients.

Conflicts of interest

None to declare.

References

- Chase RA, Pottage JC Jr, Haber MH, Kistler G, Jensen D, Levin S. Herpes simplex viral hepatitis in adults: two case reports and review of the literature. *Rev Infect Dis* 1987; 9:329-333.
- Norvell JP, Blei AT, Jovanovic BD, Levitsky J. Herpes simplex virus hepatitis: an analysis of the published literature and institutional cases. *Liver Transpl* 2007; 13:1428-1434.
- Fleming DT, McQuillan GM, Johnson RE, et al. Herpes simplex virus type 2 in the United States, 1976 to 1994. *N Engl J Med* 1997; 337:1105-1111.
- Kang AH, Graves CR. Herpes simplex hepatitis in pregnancy: a case report and review of the literature. *Obstet Gynecol Surv* 1999; 54:463-468.
- Mudido P, Marshall GS, Howell RS, Schmid DS, Steger S, Adams G. Disseminated herpes simplex virus infection during pregnancy. A case report. *J Reprod Med* 1993; 38:964-968.
- Goyert GL, Bottoms SF, Sokol RJ. Anicteric presentation of fatal herpetic hepatitis in pregnancy. *Obstet Gynecol* 1985; 65:585-588.
- Gruson D, Hilbert G, Le Bail B, et al. Fulminant hepatitis due to herpes simplex virus-type 2 in early phase of bone marrow transplantation. *Hematol Cell Ther* 1998; 40:41-44.
- Uemoto S, Tanaka K, Fujita S, et al. Infectious complications in living related liver transplantation. *J Pediatr Surg* 1994; 29:514-517.
- Tashiro T, Shigeno H, Goto J, Kikuchi H, Terao H, Nasu M. A pathological study on herpes simplex virus infections in adults. *Kansenshogaku Zasshi* 1989; 63:859-866.
- Johnson JR, Egaas S, Gleaves CA, Hackman R, Bowden RA. Hepatitis due to herpes simplex virus in marrow-transplant recipients. *Clin Infect Dis* 1992; 14:38-45.
- Dix RD, McKendall RR, Baringer JR. Comparative neurovirulence of herpes simplex virus type 1 strains after peripheral or intracerebral inoculation of BALB/c mice. *Infect Immun* 1983; 40:103-112.
- Priddy KD. Immunologic adaptations during pregnancy. *J Obstet Gynecol Neonatal Nurs* 1997; 26: 388-394.
- Brown ZA, Selke S, Zeh J, et al. The acquisition of herpes simplex virus during pregnancy. *N Engl J Med* 1997; 337:509-515.
- Velasco M, Llamas E, Guijarro-Rojas M, Ruiz-Yagüe M. Fulminant herpes hepatitis in a healthy adult: a treatable disorder? *J Clin Gastroenterol* 1999; 28:386-389.
- Fontana RJ. Should acyclovir be given to all patients presenting with acute liver failure of unknown etiology? *Nat Clin Pract Gastroenterol Hepatol*. 2008; 5:298-299.
- Levitsky J, Duddempudi AT, Lakeman FD, et al. Detection and diagnosis of herpes simplex virus infection in adults with acute liver failure. *Liver Transpl*. 2008; 14:1498-1504.

17. Kaufman B, Gandhi SA, Louie E, Rizzi R, Illei P. Herpes simplex virus: case report and review. *Clin Infect Dis* 1997; 24:334-338.
18. Ustacelebi S. Diagnosis of herpes simplex virus infections. *J Clin Virol* 2001; 21:255-259.
19. van Doornum GJ, Guldemeester J, Osterhaus AD, Niesters HG. Diagnosing herpesvirus infections by real time amplification and rapid culture. *J Clin Microbiol* 2003; 41: 576-580.
20. Ashley-Marrows R, Krantz E, Wald A. Time course of seroconversion by HerpeSelect ELISA after acquisition of genital herpes simplex virus type 1 (HSV-1) or HSV-2. *Sex Transm Dis* 2003; 30:310-314.
21. Andrews EB, Yankaskas BC, Cordero JF, Schoeffler K, Hampp S. Acyclovir in pregnancy registry: six years' experience. The Acyclovir in Pregnancy Registry Advisory Committee. *Obstet Gynecol* 1992; 79: 7—13.
22. Stone KM, Reiff-Eldridge R, White AD, et al. Pregnancy outcomes following systemic prenatal acyclovir exposure: conclusions from the international acyclovir pregnancy registry, 1984–1999. *Birth Defects Res A Clin Mol Teratol* 2004; 70: 201—207.