

# Diffuse Form of Caroli's Disease: Therapeutical Approach in a Female Patient with Recurrent Cholangitis

Cornel Iancu, Raluca Bodea, Terezia Muresan, Dana Iancu, Prabir Boruah, Nadim Al Hajjar

3rd Surgical Clinic, Cluj, Romania

## Abstract

A 49-year old female was admitted to the 3rd Surgical Clinic Cluj with clinical signs of cholangitis. She had had these symptoms for 30 years and in 2007 she was diagnosed as suffering from a diffuse form of Caroli's disease. On admission, a biological syndrome of cholestasis was noticed, associated with an inflammatory syndrome and hepatocytolysis. The imaging examinations confirmed the presence of bilateral intrahepatic cysts communicating with the biliary tree and intrahepatic lithiasis. Surgery was performed with left lobectomy, cholecystectomy, lavage of the right biliary tree and single loop cholangio-jejunal Roux-en-Y anastomosis. The patient had a favorable postoperative evolution and was discharged on the 7th day. The optimal therapeutic solution for this patient would have been a liver transplantation. However, given the emergency presentation, the surgery choice was to treat the present complications, namely the structural damage in the left lobe, the microabscesses at this level, the intrahepatic lithiasis and cholangitis. Caroli's disease, due to its complications, may impose to the surgeon to choose between different therapeutical strategies before liver transplantation.

## Key words

Caroli's disease – recurrent cholangitis – bilio-digestive derivation – liver transplant.

## Introduction

Caroli's disease is a rare clinical entity, with only 200 cases described in the literature [1]. It was first mentioned in 1906 [2], but its morphologic and clinical description was

given by Caroli in 1958 [3], stating the congenital etiology of the disease. At present, the disease is believed to be due to the cessation in the evolution of the ductal plaque which occurs in weeks 12-20 of intrauterine life, with lack of ductal remodeling at the level of the main intrahepatic ducts, followed by their dilations [4]. This is why Todani et al [5] classified the disease as type V choledochal cysts.

The disease is either localized, when the dilations of the bile ducts are present in a single lobe, mainly the left one, or diffuse, when bilateral dilations of the intrahepatic bile ducts are present. An estimated incidence of 1/1,000,000 inhabitants has been reported without any gender prevalence [6].

## Case report

A 49-year-old female was admitted to the 3rd Surgical Clinic Cluj, with previous clinical signs of cholangitis since the age of 19, being diagnosed as having Caroli's disease in 2007. On admission she was complaining of pain in the right upper abdominal quadrant, nausea, chills and fever.

The laboratory tests showed a serum increase of cholestasis enzymes, mild hepatocytolysis and an inflammatory syndrome. The ultrasound of the abdomen revealed bilateral dilations of the intrahepatic bile ducts, intrahepatic lithiasis in both lobes and a 12-mm diameter of the common bile duct. These findings were confirmed by the MRI cholangiography.

Surgery was performed in October 2009. Fibrosis of the left hepatic lobe was identified intraoperatively. This lobe was found to be compromised in terms of structure and it also presented multiple areas with abscesses of 3-10 mm. A slightly larger common bile duct with thickened walls was also identified; dissection of the hilar plaque revealed major dilations of the left hepatic duct (4 cm) as well as of the right one (3 cm).

A cholecystectomy and left lobectomy were performed (Fig. 1). The right hepatic duct was cut open starting from the sectioned area of the left hepatic duct and a large number of calculi (3 to 20 mm) were extracted (Fig. 2). Lavage of the bile ducts also identified several hundred small-sized

Received: 17.12.2009 Accepted: 18.01.2010

J Gastrointest Liver Dis

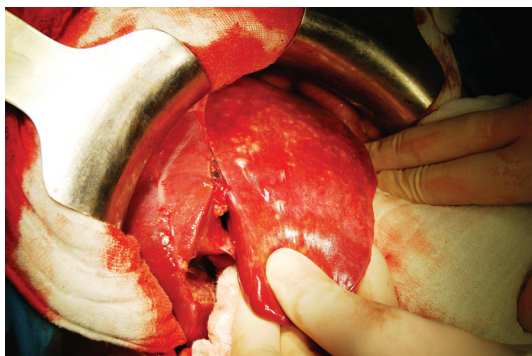
December 2010 Vol.19 No 4, 457-460

Address for correspondence:

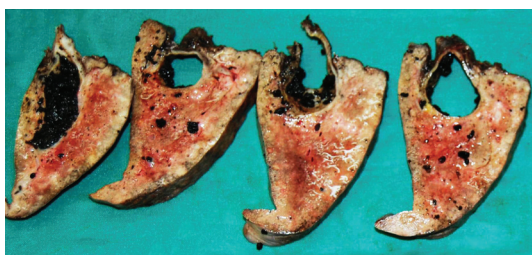Assoc. Prof. Cornel Iancu  
3rd Surgical Clinic  
Croitorilor Str. 19-21  
Cluj, 400162, Romania  
Email: dr\_cornel\_iancu@yahoo.com

calculi. Both the instrumental and the imaging investigation of the right lobe bile ducts showed their vacuity. A cholangio-jejunal Roux-en-Y anastomosis was performed with the anastomotic opening of approximately 30 mm (Fig. 3).

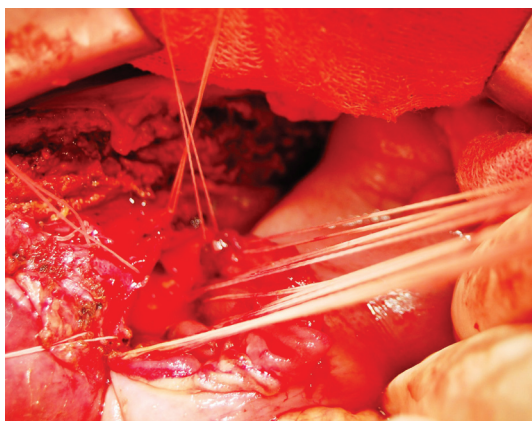
The patient had a favorable postoperative evolution and was discharged on the 7th day.



**Fig 1.** Intraoperative aspect of the liver.



**Fig 2.** Sectioned left hepatic lobe - dilated bile ducts and lithiasis.



**Fig 3.** Cholangio-jejunal Roux-en-Y large anastomosis.

## Discussion

The first clinical manifestations of Caroli's disease occur in the second and third decades of life [1] and are caused by complications or by certain morbid associations. Thus, bile stagnation in the dilated intrahepatic bile ducts favors infection and lithiasis. Patients present symptoms of cholangitis, both with or without jaundice, frequently only with fever, which delays the diagnosis. Hepatic abscesses or

sepsis can occur in the evolution of cholangitis. If congenital hepatic fibrosis is also present, portal hypertension with splenomegaly, abdominal collateral circulation, ascitis and bleeding from esophageal varices may occur [7]. Patients with Caroli's disease have an increased risk of developing cholangiocarcinoma [8].

Laboratory tests indicate cholestasis, associated with an inflammatory syndrome in the acute stages, while in the later evolution hepatocytolysis and reduction of the hepatic syntheses appear.

Imaging examinations allow the diagnosis of the disease, showing the communication between the intrahepatic cysts and the biliary tree. Thus, other pathological conditions can be excluded, namely hepatorenal polycystic disease, in which case there is no communication between the cysts and the bile ducts. Its evolution and prognosis are determined by the renal disorder. The localised or diffuse form of the disease should be established, and calculi in the intrahepatic bile ducts and signs of portal hypertension must be identified. The ultrasound and the abdominal CT are the main investigations, while the endoscopic retrograde (ERCP) or transparieto-hepatic cholangiography have the highest sensitivity. This, however, is influenced by the occurrence of postprocedural complications such as hemorrhage, bilirrhage, cholangitis or sepsis in 3% of cases [7]. Therefore, many authors recommend MRI, which is a non-invasive investigation that offers images comparable in terms of accuracy with those offered by ERCP [7, 9-11].

The elective treatment for Caroli's disease is liver resection. In the case of localized disease, without fibrosis or associated liver cirrhosis, partial hepatectomy is recommended in order to also resolve complications such as cholangitis and intrahepatic lithiasis [12-16]. Three other aspects are worth mentioning. Firstly, calculi in the contralateral lobe must be extracted and over a period of time the patient may require radiologic or endoscopic removal for residual calculi. Secondly, if Caroli's disease is localized in a segment, the removal of this only segment might not be sufficient, as many patients require extending of the operation to a hemihepatectomy [16]. Thirdly, if the disease also extends to the proximal biliary confluence, as happens in 25% of cases [12], the intervention will also include a bilio-digestive derivation with focus on the remaining hepatic duct [12, 16].

The localized form associated with fibrosis or liver cirrhosis represents an indication for liver transplantation. This can solve both the complications caused by Caroli's disease and those due to the chronic damage of the parenchyma (portal hypertension or liver failure).

The diffuse form of the disease, with no damage of hepatic parenchyma, can benefit from extended hepatic resections, if sufficient hepatic tissue can be preserved around the non-dilated bile ducts. This occurs when the disease involves all the bile ducts of one lobe, while in the contralateral lobe the dilations are localized. However, the long term results of this tactical approach are not encouraging [17-20]. If the dilations occur in the intrahepatic bile ducts

as a whole, and complications such as recurrent cholangitis or intrahepatic lithiasis are present, the optimal solution is liver transplantation, which has very good long term results [21-25].

In the diffuse form of the Caroli's disease associated with fibrosis or liver cirrhosis, liver transplantation is recommended [12,16, 18, 24, 25].

According to the European Liver Transplant Registry, 110 liver transplants were performed in patients with Caroli's disease until 2007, representing 0.2% of all transplants [16]. The average follow-up was 27 months, while the 5-year and 10-year survival rates were 86% and 76%, respectively. Habib et al [25] reported a series of 30 liver transplants performed for Caroli's disease, with an average follow-up of 93 months and 5-year and 10-year survival rates of 65% and 56%, respectively. In the USA, out of the 78,124 liver transplants performed until 2006, 104 were for Caroli's disease and the 1-year, 3-year and 5-year survival rates were 86.3%, 78.4% and 77%, respectively [24]. These results act in favor of liver transplantation, which significantly ameliorates the patient's prognosis and also eliminates the risk of cholangiocarcinoma [25, 26]. Tsuchida et al [27] studied the natural evolution of Caroli's disease and reported a mortality rate of 46% over 21 years, with an average survival of 9-40 months from the diagnosis till death, the cause of death being liver abscess, septicemia and liver failure.

Habib et al [25] recorded a high mortality rate (2/3 of the cases) in the first year after transplantation when sepsis followed. Analyzing the causes of death, they listed several risk factors. The major one was preoperative cholangitis, which must be diagnosed and treated early. Congenital liver fibrosis, old age, cholangiocarcinoma and retransplantation were also mentioned as influencing the prognosis.

We have to consider the disease complications when choosing the treatment, if liver transplantation is not available. Cholangitis should be treated with antibiotics, while for intrahepatic lithiasis ursodeoxycholic acid may be useful [7, 25]. Biliary obstructions require drainage which can be performed endoscopically, radiologically or surgically, with consideration, however, of the high risk of recurrent cholangitis [1, 7, 25].

In Romania, the waiting list for liver transplantation includes around 200 candidates while the number of actually performed transplantations varies between 10 and 40 annually [28]. The main obstacles, which reduce the number of liver transplantations are the shortage of donors and the high cost of the operation itself [28]. Under these circumstances, for our patient who represented a surgical emergency case because of the episodes of recurrent cholangitis and microabscesses in the left liver lobe, our choice was that of a more accessible approach, namely that of removing the structurally compromised lobe, evacuating the calculi of the contralateral biliary tree and ensuring a large bile drain by cholangio-jejunal Roux-en-Y anastomosis. Careful monitoring of the patient will be necessary.

## Conclusion

In patients with Caroli's disease, the tactical approach must adapt to its complications if liver transplantation is not available.

## References

1. Vasilescu C, Andrei SL, Andronesi DT, Zamfir R, Popescu I. Boli hepatice rare. In: *Chirurgia Ficatului*, vol. 1, Bucuresti: Ed Univ Carol Davila 2004, 526-530.
2. Vachell HR, Stevens WM. Case of intrahepatic calculi. *Br Med J* 1906; 1: 434-436.
3. Caroli J, Couihaud C. Une affectio nouvelle, sans doute congenitale, des voies biliares: la dilatation kystique unilobaire des canaux hepatices. *Sem Hop Paris* 1958; 14: 496-502.
4. Desmet VJ. Congenital diseases of intrahepatic bile ducts: variations on the theme „ductal plate malformation”. *Hepatology* 1992; 16: 1069-1083.
5. Todani T, Watanabe Y, Narusue M, Tabuchi K, Okajima K. Congenital bile duct cysts: Classification, operative procedures, and review of thirty-seven cases including cancer arising from choledochal cyst. *Am J Surg* 1977; 134: 263-269.
6. Giovanardi RO. Monolobar Caroli's disease in an adult. Case report. *Hepatogastroenterology* 2003; 50: 2185-2187.
7. Yonem O, Bayraktar Y. Clinical characteristics of Caroli's disease. *World J Gastroenterol* 2007; 13: 1930-1933.
8. Habib S, Shaikh OS. Caroli's disease and liver transplantation. *Liver Transpl* 2008; 14: 2-3.
9. Asselah T, Ernst O, Sergent G, L'hermine C, Paris JC. Caroli's disease: a magnetic resonance cholangiopancreatography diagnosis. *Am J Gastroenterol* 1998; 93: 109-110.
10. Sherlock S, Dooley J. *Diseases of the liver and biliary system*. 11th ed. Milano: Blackwell Sci Pub, 2002: 583.
11. Mumoli N, Cei M. Caroli disease. *Mayo Clin Proc* 2007; 82: 208.
12. Kassahun WT, Kahn T, Wittekind C, et al. Caroli's disease: liver resection and liver transplantation. Experience in 33 patients. *Surgery* 2005; 138: 888-898.
13. Espinoza R, San Martin S, Court F, Vera E, Ferreira R, Croxatto H. Hepatic resection in localized Caroli disease. *Rev Med Chil*. 2003; 131: 183-189.
14. Bockhorn M, Malago M, Lang H, et al. The role of surgery in Caroli's disease. *J Am Coll Surg* 2006; 202: 928-932.
15. Lipsett PA, Pitt HA. Surgical treatment of choledochal cysts. *J Hepatobiliary Pancreat Surg* 2003; 10: 352-359.
16. Mabrut JY, Partensky C, Jaeck D, et al. Congenital intrahepatic bile duct dilatation is a potentially curable disease. long-term results of a multi-institutional study. *Ann Surg* 2007; 246: 236-245.
17. Mercadier M, Chigot JP, Clot JP, Langlois P, Lansiaux P. Caroli's disease. *World J Surg* 1984; 8: 22-29.
18. Ammori BJ, Jenkins BL, Lim PM, Prasad KR, Pollard SG, Lodge JP. Surgical strategy for cystic disease of the liver in a western hepatobiliary center. *World J Surg* 2002; 26: 462-469.
19. Ulrich F, Steinmuller T, Settmacher U, et al. Therapy of Caroli's disease by orthotopic liver transplantation. *Transplant Proc* 2002; 34: 2279-2280.
20. Izawa K, Tanaka K, Furui J, et al. Extended right lobectomy for Caroli's disease: report of a case and review of hepatectomized cases in Japan. *Surg Today* 1993; 23: 649-655.
21. Sans M, Rimola A, Navasa M, et al. Liver transplantation in patients with Caroli's disease and recurrent cholangitis. *Transpl Int* 1997; 10: 241-244.

22. Waechter FL, Sampaio JA, Pinto RD, et al. The role of liver transplantation in patients with Caroli's disease. *Hepatogastroenterology* 2001; 48: 672-674.
23. Schiano TD, Fiel MI, Miller CM, Bodenheimer HC Jr, Min AD. Adult presentation of Caroli's syndrome treated with orthotopic liver transplantation. *Am J Gastroenterol* 1997; 92: 1938-1940.
24. Millwala F, Segev DL, Thuluvath PJ. Caroli's disease and outcomes after liver transplantation. *Liver Transpl* 2008; 14: 11-17.
25. Habib S, Shakil O, Couto OF, et al. Caroli's disease and orthotopic liver transplantation. *Liver Transpl* 2006; 12: 416-421.
26. Wang ZX, Yan LN, Li B, Zeng Y, Wen TF, Wang WT. Orthotopic liver transplantation for patients with Caroli's disease. *Hepatobiliary Pancreat Dis Int* 2008; 7: 97-100.
27. Tsuchida Y, Sato T, Sanjo K, et al. Evaluation of long-term results of Caroli's disease: 21 years' observation of a family with autosomal „dominant” inheritance, and review of the literature. *Hepatogastroenterology* 1995; 42: 175-181.
28. Popescu I, Matei E. Transplantul hepatic. In: *Tratat de Chirurgie*, vol. IX, Bucharest: Ed Acad Rom 2009, 787-822.