

Factors Associated with possibly Inappropriate Histological Evaluation of Excised Specimens in Cold-snare Polypectomy for Small Colorectal Polyps

Yuichi Shimodate¹, Junya Itakura², Motowo Mizuno¹, Rio Takezawa¹, Mami Kobayashi¹, Tatsuhiro Yamazaki¹, Akira Doi¹, Naoyuki Nishimura¹, Hirokazu Mouri¹, Kazuhiro Matsueda¹, Hiroshi Yamamoto¹

1) Department of Gastroenterology and Hepatology, and
2) Department of Pathology, Kurashiki Central Hospital, 1-1-1, Miwa, Kurashiki, Okayama, Japan

Address for correspondence:
Yuichi Shimodate M.D.
Department of Gastroenterology and Hepatology, Kurashiki Central Hospital, 1-1-1 Miwa, Kurashiki, Okayama 710-8602, Japan, ys13544@kchnet.or.jp

Received: 17.01.2018
Accepted: 28.02.2018

ABSTRACT

Background & Aims: Small colorectal polyps may be removed with cold snare polypectomy (CSP). Some of these polyps may contain unexpectedly advanced neoplasia. Thus, it is important to establish criteria for excision that will ensure that the CSP specimens are adequate for accurate histological assessment. We retrospectively investigated depth of excised small polyps and their vertical margins in patients who underwent CSP.

Method: CSP-excised specimens of 376 small colorectal polyps were examined. We histologically evaluated negative tumor vertical margins and complete resection through the muscularis mucosae, which was defined as muscularis mucosae present under the tumor along more than 80% of its horizontal axis. We also evaluated the fragmentation of the retrieved specimens.

Results: The mean size of the 376 polyps was 4.9 ± 1.4 mm, and 25 polyps (6.6%) had unexpectedly advanced histology. Thirty-two lesions (8.5%) were fragmented. In 275 (79.9%) of the remaining 344 unfragmented polyps, muscularis mucosae resection was judged complete. Vertical margins were confirmed negative in 99.6% (274/275) of polyps that had complete muscularis mucosae resection, but in only 33.3% (23/69) of polyps with incomplete resection. In 79 polyps (21%) (32 fragmented specimens and 47 unfragmented specimens), including 5 polyps with advanced histology, negative vertical margins could not be confirmed. Sessile morphology and location in the cecum were independent risk factors for incomplete muscularis mucosae resection and fragmentation.

Conclusion: Incomplete muscularis mucosae resection and fragmentation at retrieval are risk factors for inadequate histological evaluation of CSP-excised small colorectal polyps, especially for sessile polyps and polyps in the cecum.

Key words: Cold snare polypectomy – colorectal neoplasms – colorectal polyps – colorectal polypectomy – advanced colorectal neoplasia.

Abbreviations: CSP: cold snare polypectomy; CI: confidence intervals; MM: muscularis mucosae; NBI: narrow-band imaging; OR: odds ratio.

INTRODUCTION

Colorectal adenoma is a precursor lesion for colorectal cancer, and colonoscopic removal of the tumors can prevent death from colorectal cancer [1]. Cold-snare polypectomy (CSP) and cold-forceps biopsy for removal of small polyps are attracting options among gastrointestinal endoscopists because of their safety and convenience. The major difference between CSP

and conventional polypectomy is that CSP does not use electrocautery, which may injure the colonic wall and lead to perforation. Accordingly, the new European Society of Gastrointestinal Endoscopy Clinical Guideline [2] recommends CSP for small colorectal polyps.

Several reports attest the safety of cold polypectomy [3-9], and we also have reported its safety in the removal of 1,198 polyps from 474 patients in Japan [10]. However, in our study, two of the resected polyps had advanced histology, and the vertical margins were not negative, thus indicating incomplete removal of potentially malignant tissue. Factors such as tissue damage at suction retrieval and insufficient resection of submucosal tissue could have contributed to the difficulty in precise histopathological evaluation of CSP-excised tissues.

Although advanced histology is rarely present in colorectal polyps <10mm (0.8%) [11], it might be unexpectedly present. Thus, when polyps are removed with CSP, the quality and quantity of the specimens should allow accurate histological assessment, especially if CSP becomes the standard of care worldwide.

In this study, we examined CSP-excised tissues to evaluate the depth of the excised tumors and their vertical margins in order to elucidate factors associated with inability to fully evaluate the specimens histologically.

METHODS

Patients/polyps

The study was a single-center, retrospective observational study in our Japanese cohort of patients who underwent CSP for small colorectal polyps from May 2016 to May 2017 in the Kurashiki Central Hospital. Three hundred and eighty-two sessile or slightly elevated colorectal polyps, endoscopically diagnosed as colorectal neoplastic lesions less than 10 mm were removed in 139 consecutive patients; 6 of the polyps could not be retrieved; thus 376 polyps were examined. The procedure was performed by a single Board-Certificated member of the Association of Japan Gastroenterological Endoscopy Society, who has performed more than 500 CSPs.

Procedure

PCF-Q260AZI or PCF-H290ZI colonoscopes (Olympus Medical Systems, Tokyo, Japan) were used in all patients. For bowel preparation, 2 L of polyethylene glycol with ascorbic acid (Moviprep^{OR}; Ajinomoto Pharmaceutical CO, Tokyo, Japan) were used. A transparent or short hood was attached to the tip of the colonoscope to improve polyp detection. Carbon dioxide insufflation was used during the procedure. When small colorectal polyps were detected, real-time endoscopic magnifying narrow-band imaging (NBI) and magnifying chromoendoscopy, when felt needed, were performed to assess the possible presence of advanced neoplasia. Polyps considered to have advanced neoplasia by magnifying endoscopy, using the criteria of the Japan NBI Expert Team classification (Type 2B and Type 3) [12], or Kudo's pit pattern classification (V_I and V_N pit) [13], were treated by conventional endoscopic mucosal resection with electrocautery and were not included in this study. Polyp size was estimated by comparison with the diameter of the snare catheter or the opened snare placed along the polyps. All lesions were removed using CSP technique with conventional hot polypectomy snare (Captivator snare, 13-mm small oval type, or Profile snare, 11-mm extra small oval type, Boston scientific Marlborough, MA, USA), or dedicated cold polypectomy snare (Exacto cold snare, U.S Endoscopy, Mentor, Ohio). Excised polyps were retrieved by suctioning through the colonoscope's biopsy channel into a polyp trap. All en-bloc retrieved specimens were stretched and mounted on plates with pins (Fig. 1) and evaluated blindly by pathologists who had no clinical information of the lesions.

Polypectomy sites were irrigated with water jets to make it easier to detect residual tumor with magnifying narrow-band imaging; if residual tumor was suspected, additional resection was performed with the cold polypectomy technique.

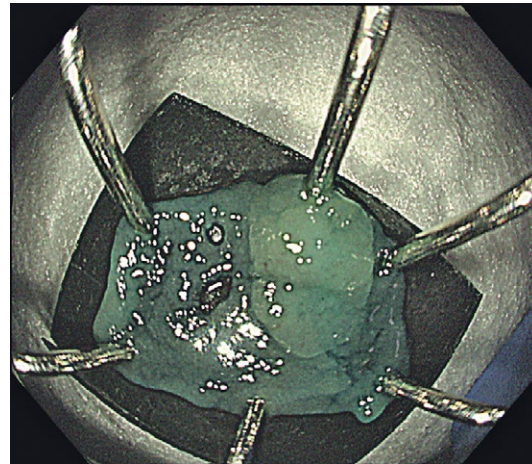


Fig. 1. Preparation for pathological assessment. All en-bloc retrieved specimens were stretched and mounted on plates with pins and evaluated blindly without pathologists having clinical information of the lesions.

Endoscopic hemostasis was performed in case of spurting or major oozing. Patients who were taking a single antithrombotic drug underwent CSP without cessation of the drug. Two weeks after polypectomy, the patients visited our outpatient clinic. They were informed about the histopathology of the resected lesions and were interviewed about post-polypectomy adverse events, including hematochezia.

Outcome measures

The primary outcome was the rate of complete resection into the muscularis mucosae (MM). Resection was defined as complete when MM was present under the tumor along more than 80% of the tumor's horizontal axis (Fig. 2). In the analysis of the completeness of resection, fragmented specimens were excluded. The secondary outcomes were the incidence of fragmentation of the retrieved specimens and the histological verification of negative tumor vertical margins. Gross morphology of the polyps was classified according to the Paris classification system [14]. Pathological diagnosis was made according to the Japanese classification of colorectal carcinomas [15]. Hyperplastic and inflammatory polyps were classified into non-neoplastic polyps.

The study was approved by the institutional Review Board of the Kurashiki Central Hospital. Written informed consent for the procedure was obtained from all patients before they underwent the procedure, and informed consent for this study was obtained with the opportunity to opt out.

Statistical analysis

For assessing efficacy, a two-sided 95% confidence interval (CI) of the rates of the incomplete MM resection, the fragmentation and the negative vertical margin were calculated. Characteristics of removed polyps were compared by using the Fisher's exact test. Risk factors for incomplete MM resection and fragmentation were analyzed with a multivariate logistic regression. For the statistical analysis, we used EZR (Saitama Medical Center, Jichi Medical University, Saitama, Japan), which is a graphical user interface for R (The R Foundation for Statistical Computing, Vienna, Austria).

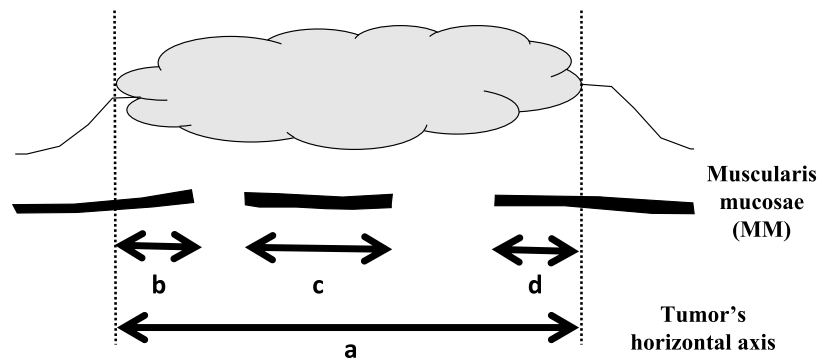


Fig. 2. Definition of complete muscularis mucosae resection. Resection was defined as complete when muscularis mucosae was present under the tumor along more than 80% of its horizontal axis, i.e. $(b + c + d)/a \geq 0.8$.

RESULTS

Characteristics of patients and polyps

Characteristics of the 139 participants are presented in Table I. The mean age was 66 ± 10.4 years, and 69.8% (97/139) were males. The major indication for colonoscopy was surveillance after partial colectomy or polypectomy for colorectal neoplasm (61.9%). Twenty-nine patients (10.8%) were taking a single antithrombotic drug.

Characteristics of the 376 analyzed colorectal polyps and their locations are presented in Table II. The polyps were most frequently located in the ascending and transverse colon, least frequently in the cecum and rectum. The polyps were slightly elevated (IIa) in 69.1% of cases and sessile in 30.9%. The mean tumor diameter was 4.9 ± 1.4 mm. At histopathological evaluation, 25 (6.6%) polyps had advanced histology: 20 high-grade adenomas and 5 intramucosal carcinomas; the mean diameter of these tumors was 5.2 ± 1.6 mm.

Treatment outcomes

Flow chart and summary of treatment outcomes are shown in Fig. 3. All 376 polyps were excised en bloc. Among them, 32 polyps (8.5%; 95%CI 5.9-11.8) were fragmented, so the histological status of their vertical margins could not be ascertained. In the 344 unfragmented intact polyps, the complete MM resection was present in 275/344 (79.9%; 95%CI

Table I. Characteristics of 139 study participants

Age mean \pm SD (range)		66 ± 10.4 (35-84)
Sex % (n)	Male	69.8 (97)
Indication of colonoscopy % (n)	Screening	0.7 (1)
	Positive FOBT	28.8 (40)
	Surveillance	61.9 (86)
	Abdominal symptoms	8.6 (12)
Use of anticoagulants % (n)	Warfarin	2.2 (3)
	DOAC	1.4 (2)
	Low-dose aspirin	5.0 (7)
	Cilostazol	0.7 (1)
	Others	1.4 (2)

FOBT: fecal occult blood test; DOAC: Direct oral anti-coagulant

Table II. Characteristics of the 376 polyps

Location % (n)	Cecum	6.6 (25/376)
	Ascending colon	26.1 (98/376)
	Transverse colon	29.2 (110/376)
	Descending colon	14.4 (54/376)
	Sigmoid colon	16.8 (63/376)
Rectum		6.9 (26/376)
Morphology % (n)	Sessile (Is)	30.9 (116/376)
	Slightly elevated (IIa)	69.1 (260/376)
Polyp size: mean \pm SD (range, mm)	All polyps	4.9 ± 1.4 (2-9)
	Polyps with advanced histology	5.2 ± 1.6 (3-9)
Pathological diagnosis % (n)	Sessile serrated adenoma	3.7 (14)
	Traditional serrated adenoma	0.3 (1)
	Tubular adenoma (low-grade)	85.6 (322)
	Tubular adenoma (high-grade) ^a	5.3 (20)
	Well differentiated carcinoma ^b	1.3 (5)
	Total of advanced histology (a+b)	6.6 (25)
	Non-neoplastic tumor*	3.7 (14)

SD: standard deviation; * hyperplastic polyps (n=11) and inflammatory polyps (n=3)

75.3-84). Among the polyps with complete MM resection, vertical margins were documented histologically negative in 274/275 (99.6%). In contrast, among the 69 polyps with incomplete MM resection, only 23 (33.3%) polyps had negative vertical margins ($p < 0.01$). Thus, among the unfragmented specimens, 297 had negative vertical margins, but 47 could not be confirmed negative (unclear). In the total of 376 polyps, the 32 fragmented specimens and the 47 unfragmented specimens failed to yield confirmation of negative vertical margins, resulting in a rate of histologically unconfirmed negative vertical margins in 79/376 (21%; 95%CI 17-25.5). Of the 25 polyps with advanced histology, vertical margins could not be adequately evaluated in 5 polyps; 2 because of tissue fragmentation and 3 due to incomplete MM resection.

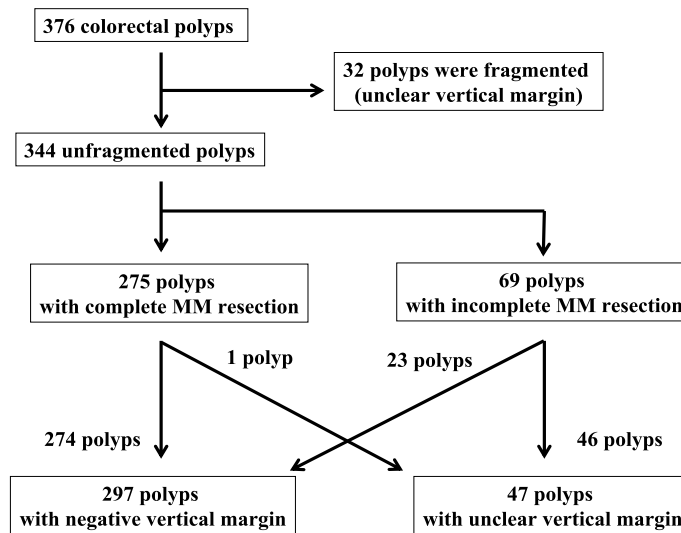


Fig. 3. Flow chart and summary of treatment outcomes of 376 polyps.

Risk factors associated with incomplete MM resection and fragmentation of resected specimens

The univariate and multivariate analyses for risk factors of incomplete MM resection of polyps are listed in Table III. Sessile morphology of polyps was a statistically significant and independent risk factor in univariate (odds ratio, OR 2.6; 95%CI: 1.46-4.72) and multivariate analyses (OR 2.64; 95%CI 1.49-4.66), but polyp size, location, histologic diagnosis, and device used for the excision of the polyps were not.

The univariate and multivariate analyses for risk factors of polyp fragmentation are listed in Table IV. Larger polyp size (6-9 mm) and location in the cecum were significant risk factors in the univariate analysis, but in the multivariate analysis, only the location at cecum was identified as an independent and significant factor (OR=5.3; 95% CI: 1.62-17.2).

Adverse events

No delayed bleeding requiring endoscopic hemostasis or colonic perforation occurred during the two-weeks postoperative period.

DISCUSSION

In this study of 376 CSP-excised polyps, we found that: 1) histologically negative vertical margins could not be documented in 21% overall, even though an experienced endoscopist performed the procedure; 2) a negative vertical margin could be documented in 99.6% of specimens with the complete MM resection, but only in 33.3% with incomplete MM resection; 3) sessile morphology of the polyps was a significant and independent risk factor for incomplete MM

Table III. Univariate and multivariate analysis for risk factors of incomplete muscularis mucosa resection

		Univariate		Multivariate	
		Odds ratio (95% CI)	p	Odds ratio (95% CI)	p
Polyp size	1-5mm	reference		reference	
	6-9mm	1.1 (0.56-1.97)	0.881	0.90 (0.47-1.73)	0.76
Location	Ascending	reference		reference	
	Cecum	1.7 (0.46-5.75)	0.371	1.44 (0.46-4.52)	0.53
	Transverse	0.7 (0.32-1.49)	0.374	0.78 (0.38-1.62)	0.5
	Descending	0.6 (0.19-1.45)	0.211	0.55 (0.22-1.36)	0.19
	Sigmoid	0.6 (0.24-1.53)	0.313	0.60 (0.26-1.41)	0.24
	Rectum	0.8 (0.22-2.66)	1	0.91 (0.29-2.89)	0.87
Morphology	Slightly elevated	reference		reference	
	Sessile	2.6 (1.46-4.72)	0.0008	2.64 (1.49-4.66)	0.0008
Pathology	Non-neoplastic	reference		reference	
	Neoplastic	3.1 (0.44-135)	0.478	3.44 (0.41-28.6)	0.25
Device	Conventional	reference		reference	
	Dedicated	1.1 (0.65-2.02)	0.686	1.07 (0.60-1.90)	0.83

Table IV. Univariate and multivariate analysis for risk factors of polyp fragmentation

		Univariate		Multivariate	
		Odds ratio (95%CI)	p	Odds ratio (95%CI)	p
Polyp size	1-5mm	reference		reference	
	6-9mm	2.6 (1.16-5.75)	0.014	2.1 (0.95-4.75)	0.068
Location	Ascending	reference		reference	
	Cecum	6.0 (1.66-22.4)	0.002	5.3 (1.62-17.2)	0.006
	Transverse	1.4 (0.49-4.59)	0.622	1.2 (0.44-3.39)	0.69
	Descending	0.2 (0.01-2.00)	0.261	0.3 (0.03-2.09)	0.2
	Sigmoid	0.7 (0.10-2.99)	0.741	0.6 (0.15-2.51)	0.5
	Rectum	1.1 (0.10-6.20)	1	0.8 (0.14-4.48)	0.78
Morphology	Slightly elevated	reference		reference	
	Sessile	1.2 (0.48-2.70)	0.684	0.9 (0.39-2.17)	0.84
Pathology	Non-neoplastic	reference		reference	
	Neoplastic	0.6 (0.12-5.63)	0.371	0.4 (0.07-2.17)	0.29
Device	Conventional	reference		reference	
	Dedicated	1.2 (0.56-2.73)	0.585	0.8 (0.37-1.86)	0.66

resection; and 4) fragmentation of specimens, which occurred in 8.5% of specimens, prevented definitive histological assessment of the vertical margins, and location in the cecum was an independent and significant risk factor for fragmentation. In addition, 6.6% of the polyps had advanced histology despite careful evaluation with image-enhanced and magnifying endoscopy before resection, and vertical margins could not be adequately evaluated in 20% of polyps with advanced histology.

It is evident that to obtain good specimens for reliable pathological evaluation, the excised small colorectal polyps must have adequate horizontal and vertical margins, and they must be retrieved intact, without fragmentation. The lack of information on resection margins was associated with an increased risk of residual cancer in adenomas with adenocarcinoma [16]. Accurate evaluation of the tumors' vertical margins and extent of invasion is essential for the assessment of polyps with advanced histology. Although the horizontal margin is often judged by endoscopic observation of the edge of CSP sites, the vertical margin can only be evaluated histologically in the excised specimens. Our finding that the ability to histologically assess the polyps' vertical margins was directly related to the length of horizontal MM indicates that adequate MM resection is mandatory to achieve precise pathological assessment. We evaluated MM resection by measuring the length of MM under the tumor along its horizontal axis, and defined complete MM resection as more than 80% of the length. When evaluated this way, the rate of complete MM resection was 79.9% among 344 unfragmented polyps in CSP. In reports on the quality of CSP based on histological evaluation, complete resection rates have varied widely (59%-94%) [4-5, 17, 18]. Hirose et al. [18] discussed the importance of adequate MM resection, showing that the absence of MM in the excised specimens was associated with low confirmation rate of histological margins. We know of no report in which the vertical margin in CSP-excised specimens was evaluated as in our study. We also identified sessile polyp

morphology as a risk factor for incomplete MM resection. Thus, special care must be taken to resect sessile polyps with adequate MM to permit reliable assessment of the vertical margin. Establishment of a verifiable CSP technique to achieve a good MM resection is awaited.

Our study has illustrated that the fragmentation of polyps is a problem with CSP. CSP-excised specimens are usually small and fragile and are usually retrieved by suctioning through the narrow biopsy channel of the colonoscope into the polyp trap; fragmentation apparently occurs in this process. Use of endoscopes with a wide biopsy channel and low suction pressure during retrieval are measures that should be evaluated to avert the fragmentation. Our finding that polyps located in the cecum seem especially prone to the fragmentation is unexplained but indicate that caution in the excision and retrieval of small cecal polyps is indicated.

Limitations of our study are that CSP was conducted by a single endoscopist and the study population is not large. Large-scale studies including endoscopists of various skills and experience should be conducted.

CONCLUSION

Incomplete resection through the muscularis mucosae and fragmentation at retrieval are risk factors for the inadequate histological evaluation of CSP-excised small colorectal polyps, especially for the sessile polyps and polyps in the cecum. Measures to avoid these problems are necessary before CSP becomes the standard of care for excision of small colorectal polyps.

Conflicts of interest: None to declare.

Authors' contribution: Y.S analyzed the results and wrote the manuscript, M.M supervised the data analysis and manuscript preparation, J.I. performed histological evaluation, Y.S, R.T, M.K, T.Y, A.D, N.N, H.M, K.M and H.Y collected clinical data.

Acknowledgement: Dr. Yuichi Shimodate received a travel grant from United European Gastroenterology Week 2017, for travel to Barcelona, Spain. This work was presented in part at the 25th United European Gastroenterology Week, Barcelona, October 2017.

REFERENCES

- Zauber AG, Winawer SJ, O'Brien MJ, et al. Colonoscopic polypectomy and long-term prevention of colorectal-cancer deaths. *N Engl J Med* 2012;366: 687-696. doi:[10.1056/NEJMoa1100370](https://doi.org/10.1056/NEJMoa1100370)
- Ferlitsch M, Moss A, Hassan C, et al. Colorectal polypectomy and endoscopic mucosal resection (EMR):European Society of Gastrointestinal Endoscopy (ESGE) Clinical Guideline. *Endoscopy* 2017;49:270-297. doi:[10.1055/s-0043-102569](https://doi.org/10.1055/s-0043-102569)
- Repici A, Hassan C, Vitetta E, et al. Safety of cold polypectomy for <10mm polyps at colonoscopy:a prospective multicenter study. *Endoscopy* 2012;44:27-31. doi:[10.1055/s-0031-1291387](https://doi.org/10.1055/s-0031-1291387)
- Takeuchi Y, Yamashina T, Matsuura N, et al. Feasibility of cold snare polypectomy in Japan: A pilot study. *World J Gastrointest Endosc* 2015;7:1250-1256. doi:[10.4253/wjge.v7.i17.1250](https://doi.org/10.4253/wjge.v7.i17.1250)
- Horiuchi A, Nakayama Y, Kajiyama M, Tanaka N, Sano K, Graham DY. Removal of small colorectal polyps in anticoagulated patients: a prospective randomized comparison of cold snare and conventional polypectomy. *Gastrointest Endosc* 2014;79:417-423. doi:[10.1016/j.gie.2013.08.040](https://doi.org/10.1016/j.gie.2013.08.040)
- Ichise Y, Horiuchi A, Nakayama Y, Tanaka N. Prospective randomized comparison of cold snare polypectomy and conventional polypectomy for small colorectal polyps. *Digestion* 2011;84:78-81. doi:[10.1159/000323959](https://doi.org/10.1159/000323959)
- Paspatis GA, Tribonias G, Konstantinidis K, et al. A prospective randomized comparison of cold vs hot snare polypectomy in the occurrence of postpolypectomy bleeding in small colonic polyps. *Colorect Dis* 2011;13:e345-e348. doi:[10.1111/j.1463-1318.2011.02696.x](https://doi.org/10.1111/j.1463-1318.2011.02696.x)
- Makino T, Horiuchi A, Kajiyama M, Tanaka N, Sano K, Maetani I. Delayed Bleeding Following Cold Snare Polypectomy for Small Colorectal Polyps in Patients Taking Antithrombotic Agents. *J Clin Gastroenterol* 2017 Jan 27. doi:[10.1097/MCG.0000000000000802](https://doi.org/10.1097/MCG.0000000000000802)
- Fujiya M, Sato H, Ueno N, et al. Efficacy and adverse events of cold vs hot polypectomy: A meta-analysis. *World J Gastroenterol* 2016;22:5436-5444. doi:[10.3748/wjg.v22.i23.5436](https://doi.org/10.3748/wjg.v22.i23.5436)
- Shimodate Y, Mizuno M, Takezawa R, et al. Safety of cold polypectomy for small colorectal neoplastic lesions:a prospective cohort study in Japan. *Int J Colorectal Dis* 2017;32:1261-1266. doi:[10.1007/s00384-017-2856-y](https://doi.org/10.1007/s00384-017-2856-y)
- Gupta N, Bansal A, Rao D, et al. Prevalence of advanced histological features in diminutive and small colon polyps. *Gastrointest Endosc* 2012;75:1022-1030. doi:[10.1016/j.gie.2012.01.020](https://doi.org/10.1016/j.gie.2012.01.020)
- Sumimoto K, Tanaka S, Shigita K, et al. Diagnostic performance of Japan NBI Expert Team classification for differentiation among noninvasive, superficially invasive, and deeply invasive colorectal neoplasia. *Gastrointest Endosc* 2017;86:700-709. doi:[10.1016/j.gie.2017.02.018](https://doi.org/10.1016/j.gie.2017.02.018)
- Tanaka S, Kaltenbach T, Chayama K, Soetikno R. High-magnification colonoscopy (with videos). *Gastrointest Endosc* 2006;64:604-613. doi:[10.1016/j.gie.2006.06.007](https://doi.org/10.1016/j.gie.2006.06.007)
- Endoscopic Classification Review Group. Update on the paris classification of superficial neoplastic lesions in the digestive tract. *Endoscopy* 2005;37:570-578. doi:[10.1055/s-2005-861352](https://doi.org/10.1055/s-2005-861352)
- Japanese classification of colorectal carcinoma, second English edition. Kanehara & CO Ltd, Tokyo, Japan 2009.
- Steigen SE, Isaksen V, Skjæveland A, Vonen B. Adenomas with adenocarcinoma:a study evaluating the risk of residual cancer and lymph node metastasis. *Scand J Surg* 2013;102:90-95. doi:[10.1177/1457496913482253](https://doi.org/10.1177/1457496913482253)
- Horiuchi A, Hosoi K, Kajiyama M, Tanaka N, Sano K, Graham DY. Prospective, randomized comparison of 2 methods of cold snare polypectomy for small colorectal polyps. *Gastrointest Endosc* 2015;82:686-692. doi:[10.1016/j.gie.2015.02.012](https://doi.org/10.1016/j.gie.2015.02.012)
- Hirose R, Yoshida N, Murakami T, et al. Histopathological analysis of cold snare polypectomy and its indication for colorectal polyps 10-14 mm in diameter. *Dig Endosc* 2017;29:594-601. doi:[10.1111/den.12825](https://doi.org/10.1111/den.12825)