

# Laparoscopic Transgastric versus Endoscopic Drainage of a Large Pancreatic Pseudocyst. A Case Report

Mircea Beuran<sup>1,2</sup>, Ionut Negoii<sup>1,2</sup>, Fausto Catena<sup>3</sup>, Massimo Sartelli<sup>4</sup>, Sorin Hostiuc<sup>1,5</sup>, Sorin Paun<sup>1,2</sup>

1) Carol Davila University  
of Medicine and Pharmacy

Bucharest, Romania

2) Emergency Hospital of  
Bucharest, Romania

3) Department of Emergency  
Surgery, Maggiore Hospital,  
Parma, Italy

4) Department of Surgery,  
Macerata Hospital, Macerata,  
Italy

5) Mina Minovici National  
Institute of Legal Medicine,  
Romania

## ABSTRACT

**Background:** Pancreatic pseudocysts are the most common complication of acute and chronic pancreatitis. They account for 75% of the cystic lesions of the pancreas.

**Case report:** A 37 year-old woman was admitted three months after an episode of severe acute pancreatitis with a large tumor mass located in her left abdomen, abdominal tenderness and asthenia. Abdominal Computed Tomography (CT) revealed a giant pancreatic pseudocyst of 23/15/12 centimeters. We performed an anterior laparoscopic transgastric cystogastrostomy. The postoperative clinical course was uneventful, and she was discharged nine days later. After another month she was re-admitted for general malaise and fever. We performed endoscopic evaluation of the cystogastrostomy patency followed by lavage of the pseudocyst cavity. After five days of broad spectrum antibiotic therapy the clinical course started to improve and the patient was discharged after another eight days. One- and two-year follow-ups revealed no remnant cavity.

**Conclusions:** Laparoscopic transgastric cystogastrostomy is a feasible option for selected patients with pancreatic pseudocysts. Careful patients' evaluation in a multidisciplinary team, including imaging specialists, dedicated gastroenterologists with experience in advanced interventional techniques and pancreatic surgeons, balancing between watchful waiting and step-up minimally invasive approach offers the best tailored approach for a specific patient.

**Key words:** pancreatic pseudocyst – laparoscopy – minimally invasive – acute pancreatitis.

## Address for correspondence:

**Ionut Negoii**, MD PhD

Carol Davila University of  
Medicine and Pharmacy  
Bucharest,

General Surgery Department,

Emergency Hospital of  
Bucharest,

8, Floreasca Str.

014461, Bucharest

Romania

[negoiiionut@gmail.com](mailto:negoiiionut@gmail.com)

## INTRODUCTION

Pancreatic pseudocysts are the most common complication of acute and chronic pancreatitis [1], with an incidence of 14.6% in acute pancreatitis and 41.8% in acute-on-chronic pancreatitis [2–5]. They account for 75% of the cystic lesions of the pancreas [6]. According to the Atlanta 2012 revised classification, the pancreatic pseudocyst is an encapsulated collection of fluid with a well defined inflammatory wall, minimal or no necrosis, which often requires for maturation more than four weeks after the onset of an acute pancreatic episode [7]. Therapeutic approach of pancreatic pseudocysts should be decided after high resolution

imaging and clinical evaluation. Most pseudocysts with a diameter of less than 4 centimeters (cm) will resolve spontaneously, or will remain clinically stable without further complications. Pseudocysts with a diameter between 4 to 6 cm can be managed by watchful waiting to see if they are asymptomatic or stable on follow-up imagery [8]. These pseudocysts can resolve spontaneously, but serious complications may occur in 10% of cases [9, 10]. Pseudocysts larger than 6 cm and persistent more than 6 weeks should be managed by a percutaneous, endoscopic or surgical approach [11].

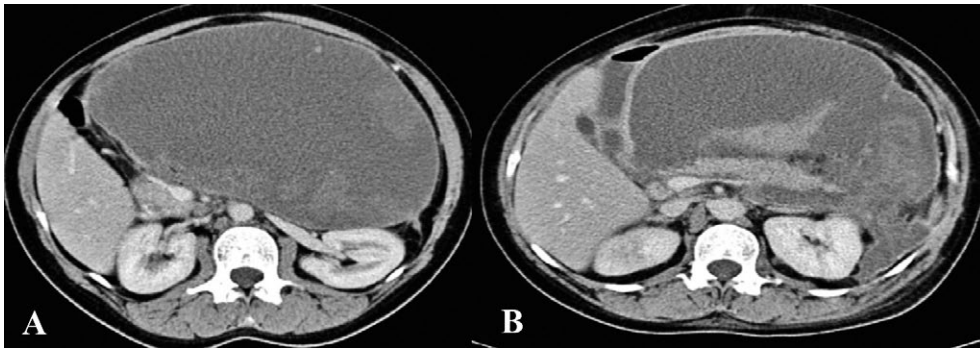
The objective of this case report is to illustrate the minimally invasive management of giant pancreatic pseudocysts.

## CASE REPORT

A 37 year-old woman was admitted three months after an episode of severe acute pancreatitis with a large tumor mass in the left abdomen, abdominal tenderness and asthenia. Abdominal Computed Tomography (CT) revealed a giant pancreatic pseudocyst of 23/15/12 cm, with the lower border in the iliac fossa, and compression of the surrounding organs (stomach, duodenum, left colon, spleen, and left kidney). CT

Received: 28.02.2016

Accepted: 21.03.2016



**Fig. 1.** Preoperative CT, axial section, three months after the onset of severe acute pancreatitis, revealing a large pseudocyst (A) that contained important necrotic material (B).

showed a large amount of necrotic tissue inside the pseudocyst (Fig. 1).

We decided to perform an anterior laparoscopic transgastric approach, with the abdomen accessed using an open technique. After the anterior gastrotomy, the pseudocyst was punctured-aspirated through the posterior gastric wall: 2,300 ml of dark-brown fluid was aspirated. We performed a cystogastrostomy using a continuous monofilament nonresorbable suture.

The postoperative clinical course was uneventful. On the 7<sup>th</sup> postoperative day the CT scan showed a mild edema of the cystogastrostomy. The size of the pseudocyst decreased to 18/11/6 cm (Fig. 2 A). The patient was discharged after 9 days.

A month later the patient was re-admitted for general malaise and fever. Clinical examination revealed no signs of peritoneal irritation. Abdominal CT showed a remnant cavity of 11.8/7.5/5 cm (Fig. 2 B). We performed an endoscopic lavage of the pseudocyst cavity, with the tip of the endoscope through the cystogastrostomy. The patient received antibiotic therapy (Imipenem/Cilastatin, 2 g per day) for 5 days, and the clinical course was favorable. The patient was discharged after 8 days from admission.

At the one-year follow-up there was no remnant cavity on abdominal CT (Fig. 3).

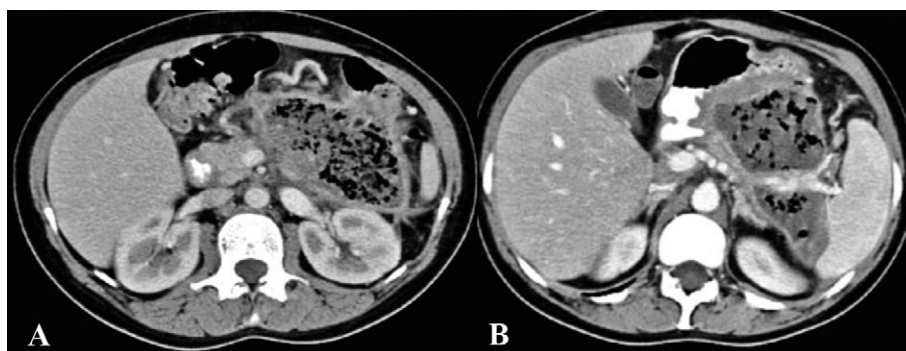
At the two-year follow-up, under pharmacologic treatment of hyperlipidemia, there was no recurrence of acute pancreatitis.

## DISCUSSION

We present the case of a successful minimally invasive management of a giant pancreatic pseudocyst in a young woman, three months after an episode of severe metabolic acute pancreatitis.

Therapeutic options for a pancreatic pseudocyst include surgical, endoscopic, and percutaneous drainage, which are complementary to each other rather than conflicting (Table I) [10, 11]. Nowadays, as the laparoscopic Whipple resections have become more popular worldwide, there is no doubt about the feasibility of laparoscopic approach in pancreatic diseases [13]. For pancreatic pseudocysts, the laparoscopic approach offers the same results as open drainage procedures, maintaining the known benefits of a minimally invasive approach (Table II). The initial laparoscopic transgastric technique, described by Way et al. involves the usage of three radially expandable trocars (2 of 12 mm and one of 5 mm) inserted through the anterior gastric wall [14]. This intragastric approach has as main disadvantages the lack of triangulation of the working instruments and difficult access of the pseudocyst after its evacuation [15]. For our patient we used a true laparoscopic transgastric approach. Gibson et al. described a useful method for initial puncturing of the pseudocyst in the second technique, using a radially progressive expandable trocar [15].

Khaled et al. published a case-matched comparative study of 40 patients, including 30 cases in the laparoscopy group



**Fig. 2.** Postoperative CT: A) On the 7<sup>th</sup> postoperative day the CT revealed partial evacuation of the pseudocyst, which had a 18/11/6 cm in diameter; B) one month after surgery the CT showed a reduction of the pseudocyst's diameters (11.8/7.5.5 cm) with edema of the cystogastrostomy. In this axial section the splenic vessels trajectory through the pseudocyst can be observed.

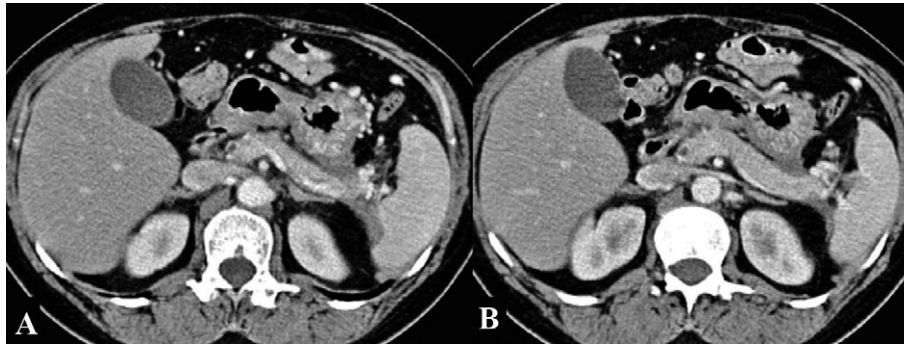


Fig. 3. Postoperative CT, at one-year follow-up, revealing complete resolution of the pseudocyst.

and 10 cases in the open cystogastrostomy group [16]. The laparoscopic approach had a shorter operating time (62 versus 95 min,  $p=0.035$ ), a lower rate of postoperative morbidity (10% versus 60%,  $p=0.024$ ) and a shorter in-hospital stay (6.2 versus 11 days,  $p=0.038$ ). The authors concluded that the laparoscopic approach should be preferred where relevant expertise is available [16]. A meta-analysis of 5 comparative studies, including 255 patients, published in 2015 and comparing endoscopic with surgical treatment for pancreatic pseudocysts concluded that the endoscopic approach may be the first line treatment [17]. The surgical group had a higher success rate than the endoscopic group (OR=0.43, 95%CI 0.2 to 0.95,  $p=0.04$ ), with no statistical significant differences between the two groups regarding the adverse events (OR=0.67, 95% CI 0.33 to 1.36,  $p=0.27$ ) and recurrence rate (OR=1.53, 95% CI 0.37 to 6.39,  $p=0.56$ ) [17].

Melman et al. evaluated the clinical outcomes after laparoscopic (16 patients), endoscopic (45 patients), and open (22 patients) cystogastrostomy for pancreatic pseudocysts [18]. Grade 2 or greater complications were noticed in 31.5%, 15.6%, and 22.7% in laparoscopic, endoscopic and open group, respectively ( $p>0.05$ ). The primary compared with overall success rate (defined as cyst resolution) was 87.5% versus 93.8% for laparoscopic, 51.1% versus 84.6% for endoscopic, and 81.2% versus 90.9% for the open group ( $p<0.01$  for surgery versus endoscopy). On the other hand, primary endoscopic failures can be managed by repeated procedures, with a similar overall success rate [18].

Palanivelu et al. published their 12 years experience in management of pancreatic pseudocysts [19]. Out of 108 patients, laparoscopic cystogastrostomy was performed in 90 (83.4%) cases, laparoscopic cystojejunostomy in 8 (7.4%) cases, open cystogastrostomy in 2 (1.8%) cases and laparoscopic external drainage in 8 cases (7.4%). Two patients were re-operated for bleeding and gastric outlet obstruction [19].

In the study by Hauters et al. that included 17 cases, 2 patients were readmitted during the first 3 postoperative weeks due to secondary infection of the pancreatic pseudocyst. In the first case an early closure of the cystogastrostomy was managed by an endoscopic stent placement [20]. This scenario was very similar to our case, where endoscopic confirmation of the anastomosis patency and lavage of the pseudocyst cavity favored the pseudocyst evacuation.

The endoscopic approach is technically successful in 70–100% of cases of walled-off pancreatic fluid collections, which includes pancreatic pseudocyst and walled-off pancreatic necrosis. Tyberg et al. reported a clinical success rate between 70–100%, with a complication rate of up to 18% [21]. The success rate of an endoscopic approach is lower following acute (over 70%) compared to chronic pancreatitis (over 90%) [22–27]. In the walled-off collection that includes solid debris, the recurrence rate exceeds 30% [26, 28].

Binmoeller et al. reported 53 patients with symptomatic pancreatic pseudocysts, managed by transpapillary drainage in 33 cases, transmural drainage in 20 cases, and by a combined approach in the remaining 4 cases [29]. The mean diameter of the pseudocysts was 7 cm, in 92% of cases the cause being chronic pancreatitis. Complications occurred in 11% of cases, after a mean follow-up of 22 months [29]. In patients with a pancreatic duct disruption that could be bridged, transpapillary pancreatic duct stenting improved outcomes in patients with endoscopic transmural drainage of peripancreatic fluid collections [30]. Trevino et al. reviewed 110 patients with endoscopic transmural pancreatic fluid collection drainage (62% pseudocysts), in 40 (36%) patients being added a simultaneous pancreatic duct stenting [30]. Even after multivariable analysis, the patients with a pancreatic duct stenting were significantly more likely to have a treatment success (risk ratio 1.14, 95% confidence interval: 1.01–1.29,  $p=0.0036$ ).

Table I. Comparison of different interventional techniques addressing pancreatic pseudocysts [35–39].

Outcome	Therapeutic option	Percutaneous drainage	Endoscopic drainage	Laparoscopic surgical drainage	Open surgical drainage
Fluid collection resolution success rate			70–80%	92%	
Recurrence rate		70%	10–15%	3%	
Mortality			0.2%	0%	5%
Complications			10–15%	9%	25%
Pancreatic fistula		>20%			

**Table II.** Laparoscopic approach in patients with pancreatic pseudocysts, series including more than 10 patients

Study/Location	Number of patients	Success rate	Postoperative complications
Palanivelu et al./India [19]	108	98 (91%)	9 (8%)
Gibson et al./UK [15]	36	36 (100%)	1 (2.7%)
Hamza et al./UK [40]	28	26 (92.9%)	1 (3.3%)
Park & Heniford/USA [41]	28	27 (96%)	2 (7%)
Mori et al./Japan [14]	17	14 (82%)	3 (18%)
Hauters et al./Belgium [20]	17	16 (94%)	2 (12%)
Hindmarsh et al./UK [42]	15	12 (80%)	2 (13%)

A randomized controlled trial compared 20 patients treated with endoscopic cystogastrostomy and 20 patients treated surgically [31]. After a follow-up of 24 months none of the patients from the endoscopic group had a recurrence, compared to one from the surgical group. There were no differences in the treatment outcome, complications, or re-interventions between the groups. Patients from the endoscopic group had a shorter hospital stay (2 versus 6 days,  $p < 0.001$ ) and lower costs (\$7011 versus \$15,052,  $p = 0.003$ ). A major drawback of this study is that all surgical interventions were performed using an open approach, even though laparoscopy is a more suitable competitor for endoscopic drainage [32]. On the other hand, this paper did not present the cause of the pseudocysts (acute versus chronic pancreatitis) and diagnosed the pseudocysts using CT. It should be noted that CT can detect necrotic debris in only 22% of cases, compared with 89% for MRI [33]. In our case, one of the most powerful indications for a surgical approach was the large amount of necrotic debris inside the fluid collection. In patients with walled-off pancreatic fluid collections that include debris, EUS-guided drainage using a combination of transmural stents and nasocystic drain improves clinical outcomes compared to stents only [34]. Siddiqui et al. compared 63 patients with nasocystic stents alongside stents with 24 patients with transmural stents, in all cases solid debris being present inside the pancreatic pseudocysts [34]. The short-term success rate was three times greater for patients with both nasocystic tube and stents ( $p = 0.03$ ). After a follow-up of 12 months, complete resolution was significantly higher in the combined group (79% versus 58%,  $p = 0.059$ ), and the stent occlusion was significantly lower (13% versus 33%,  $p = 0.03$ ).

## CONCLUSIONS

Laparoscopic transgastric cystogastrostomy is a feasible option in selected patients with pancreatic pseudocysts. Careful patients evaluation in a multidisciplinary team, including imaging specialists, gastroenterologists with experience in advanced interventional techniques and pancreatic surgeons, balancing between watchful waiting and a step-up minimally invasive approach offers the best tailored approach for a specific patient.

**Conflicts of interest.** None to declare.

**Authors' contributions:** M.B.: conception and design of the study, critical revision; I.N.: data acquisition, analysis and interpretation, manuscript drafting; F. C. and M.S.: interpretation of data, manuscript revision; S.H.: data acquisition, manuscript revision; S.P.: data interpretation, manuscript revision. All authors gave their approval for the final version of the manuscript.

## REFERENCES

1. Aghdassi AA, Mayerle J, Kraft M, Sielenkämper AW, Heidecke CD, Lerch MM. Pancreatic pseudocysts--when and how to treat? *HPB (Oxford)* 2006; 8: 432–441. doi: [10.1080/13651820600748012](https://doi.org/10.1080/13651820600748012)
2. Bradley EL, Gonzalez AC, Clements JL Jr. Acute pancreatic pseudocysts: incidence and implications. *Ann Surg* 1976; 184: 734–737.
3. Maringhini A, Uomo G, Patti R, et al. Pseudocysts in acute nonalcoholic pancreatitis: incidence and natural history. *Dig Dis Sci* 1999; 44: 1669–1673. doi: [10.1023/A:1026691700511](https://doi.org/10.1023/A:1026691700511)
4. London NJ, Neoptolemos JP, Lavelle J, Bailey I, James D. Serial computed tomography scanning in acute pancreatitis: a prospective study. *Gut* 1989; 30: 397–403.
5. Kim KO, Kim TN. Acute pancreatic pseudocyst: incidence, risk factors, and clinical outcomes. *Pancreas* 2012; 41: 577–581. doi: [10.1097/MPA.0b013e3182374def](https://doi.org/10.1097/MPA.0b013e3182374def)
6. Naoum E, Zavos A, Goudis K, et al. Pancreatic pseudocysts: 10 years of experience. *J Hepatobiliary Pancreat Surg* 2003; 10: 373–376. doi: [10.1007/s00534-002-0828-1](https://doi.org/10.1007/s00534-002-0828-1)
7. Banks PA, Bollen TL, Dervenis C, et al; Acute Pancreatitis Classification Working Group. Classification of acute pancreatitis--2012: revision of the Atlanta classification and definitions by international consensus. *Gut* 2013; 62: 102–111. doi: [10.1136/gutjnl-2012-302779](https://doi.org/10.1136/gutjnl-2012-302779)
8. Ramos-De la Medina A, Reid-Lombardo KM, Sarr MG. Strategies for surgical treatment of pseudocysts after acute pancreatitis. In: Beger HG, Warshaw AL, Büchler MW, et al. (Eds.). *The Pancreas: An Integrated Textbook of Basic Science, Medicine, and Surgery*. Second Edition, Blackwell Publishing Limited; 2008: 321–330.
9. Nealon WH, Walser E. Main pancreatic ductal anatomy can direct choice of modality for treating pancreatic pseudocysts (surgery versus percutaneous drainage). *Ann Surg* 2002; 235: 751–758. doi: [10.1097/0000658-200206000-00001](https://doi.org/10.1097/0000658-200206000-00001)
10. Yeo CJ, Sarr MG. Cystic and pseudocystic diseases of the pancreas. *Curr Probl Surg* 1994; 31: 165–243.
11. Sheng QS, Chen DZ, Lang R, et al. Laparoscopic cystogastrostomy for the treatment of pancreatic pseudocysts: a case report. *World J Gastroenterol* 2008; 14: 4841–4843. doi: [10.3748/wjg.14.4841](https://doi.org/10.3748/wjg.14.4841)



12. Sharma D, Kataria S, Pathak R, Barua B, Lal R. Laparoscopic drainage of a large pancreatic pseudocyst. *JSLs* 2012; 16: 675–677. doi: [10.4293/108680812X13517013316870](https://doi.org/10.4293/108680812X13517013316870)
13. Adam MA, Choudhury K, Dinan MA, et al. Minimally Invasive Versus Open Pancreaticoduodenectomy for Cancer: Practice Patterns and Short-term Outcomes Among 7061 Patients. *Ann Surg* 2015; 262: 372–377. doi: [10.1097/SLA.0000000000001055](https://doi.org/10.1097/SLA.0000000000001055)
14. Mori T, Abe N, Sugiyama M, Atomi Y. Laparoscopic pancreatic cystgastrostomy. *J Hepatobiliary Pancreat Surg* 2002; 9: 548–554. doi: [10.1007/s005340200072](https://doi.org/10.1007/s005340200072)
15. Gibson SC, Robertson BF, Dickson EJ, McKay CJ, Carter CR. ‘Step-port’ laparoscopic cystgastrostomy for the management of organized solid predominant post-acute fluid collections after severe acute pancreatitis. *HPB (Oxford)* 2014; 16: 170–176. doi: [10.1111/hpb.12099](https://doi.org/10.1111/hpb.12099)
16. Khaled YS, Malde DJ, Packer J, et al. Laparoscopic versus open cystgastrostomy for pancreatic pseudocysts: a case-matched comparative study. *J Hepatobiliary Pancreat Sci* 2014; 21: 818–823. doi: [10.1002/jhbp.138](https://doi.org/10.1002/jhbp.138)
17. Zhao X, Feng T, Ji W. Endoscopic versus surgical treatment for pancreatic pseudocyst. *Dig Endosc* 2016; 28: 83–91. doi: [10.1111/den.12542](https://doi.org/10.1111/den.12542)
18. Melman L, Azar R, Beddow K, et al. Primary and overall success rates for clinical outcomes after laparoscopic, endoscopic, and open pancreatic cystgastrostomy for pancreatic pseudocysts. *Surg Endosc* 2009; 23:267–271. doi: [10.1007/s00464-008-0196-2](https://doi.org/10.1007/s00464-008-0196-2)
19. Palanivelu C, Senthilkumar K, Madhankumar MV, et al. Management of pancreatic pseudocyst in the era of laparoscopic surgery--experience from a tertiary centre. *Surg Endosc* 2007; 21: 2262–2267. doi: [10.1007/s00464-007-9365-y](https://doi.org/10.1007/s00464-007-9365-y)
20. Hauters P, Weerts J, Navez B, et al. Laparoscopic treatment of pancreatic pseudocysts. *Surg Endosc* 2004; 18: 1645–1648. doi: [10.1007/s00464-003-9280-9](https://doi.org/10.1007/s00464-003-9280-9)
21. Tyberg A, Karia K, Gabr M, et al. Management of pancreatic fluid collections: A comprehensive review of the literature. *World J Gastroenterol* 2016; 22: 2256–2270. doi: [10.3748/wjg.v22.i7.2256](https://doi.org/10.3748/wjg.v22.i7.2256)
22. Krüger M, Schneider AS, Manns MP, Meier PN. Endoscopic management of pancreatic pseudocysts or abscesses after an EUS-guided 1-step procedure for initial access. *Gastrointest Endosc* 2006; 63: 409–416. doi: [10.1016/j.gie.2005.11.047](https://doi.org/10.1016/j.gie.2005.11.047)
23. Kozarek RA, Ball TJ, Patterson DJ, Freeny PC, Ryan JA, Traverso LW. Endoscopic transpapillary therapy for disrupted pancreatic duct and peripancreatic fluid collections. *Gastroenterology* 1991; 100: 1362–1370.
24. Kahaleh M, Shami VM, Conaway MR, et al. Endoscopic ultrasound drainage of pancreatic pseudocyst: a prospective comparison with conventional endoscopic drainage. *Endoscopy* 2006; 38: 355–359. doi: [10.1055/s-2006-925249](https://doi.org/10.1055/s-2006-925249)
25. Antillon MR, Shah RJ, Stigmann G, Chen YK. Single-step EUS-guided transmural drainage of simple and complicated pancreatic pseudocysts. *Gastrointest Endosc* 2006; 63: 797–803. doi: [10.1016/j.gie.2005.10.025](https://doi.org/10.1016/j.gie.2005.10.025)
26. Hookey LC, Debroux S, Delhaye M, Arvanitakis M, Le Moine O, Devière J. Endoscopic drainage of pancreatic-fluid collections in 116 patients: a comparison of etiologies, drainage techniques, and outcomes. *Gastrointest Endosc* 2006; 63: 635–643. doi: [10.1016/j.gie.2005.06.028](https://doi.org/10.1016/j.gie.2005.06.028)
27. Seewald S, Groth S, Omar S, et al. Aggressive endoscopic therapy for pancreatic necrosis and pancreatic abscess: a new safe and effective treatment algorithm (videos). *Gastrointest Endosc* 2005; 62: 92–100. doi: [10.1016/S0016-5107\(05\)00541-9](https://doi.org/10.1016/S0016-5107(05)00541-9)
28. Baron TH, Harewood GC, Morgan DE, Yates MR. Outcome differences after endoscopic drainage of pancreatic necrosis, acute pancreatic pseudocysts, and chronic pancreatic pseudocysts. *Gastrointest Endosc* 2002; 56: 7–17. doi: [10.1067/mge.2002.125106](https://doi.org/10.1067/mge.2002.125106)
29. Binmoeller KE, Seifert H, Walter A, Soehendra N. Transpapillary and transmural drainage of pancreatic pseudocysts. *Gastrointest Endosc* 1995; 42: 219–224.
30. Trevino JM, Tamhane A, Varadarajulu S. Successful stenting in ductal disruption favorably impacts treatment outcomes in patients undergoing transmural drainage of peripancreatic fluid collections. *J Gastroenterol Hepatol* 2010; 25: 526–531. doi: [10.1111/j.1440-1746.2009.06109.x](https://doi.org/10.1111/j.1440-1746.2009.06109.x)
31. Varadarajulu S, Bang JY, Sutton BS, Trevino JM, Christein JD, Wilcox CM. Equal efficacy of endoscopic and surgical cystogastrostomy for pancreatic pseudocyst drainage in a randomized trial. *Gastroenterology* 2013; 145: 583–590.e1. doi: [10.1053/j.gastro.2013.05.046](https://doi.org/10.1053/j.gastro.2013.05.046)
32. Talukdar R, Sundaram M, Nageshwar Reddy D. Endoscopic vs surgical drainage of pancreatic pseudocysts. *Gastroenterology* 2014; 146: 319–320. doi: [10.1053/j.gastro.2013.07.056](https://doi.org/10.1053/j.gastro.2013.07.056)
33. Morgan DE, Baron TH, Smith JK, Robbin ML, Kenney PJ. Pancreatic fluid collections prior to intervention: evaluation with MR imaging compared with CT and US. *Radiology* 1997; 203: 773–778. doi: [10.1148/radiology.203.3.9169703](https://doi.org/10.1148/radiology.203.3.9169703)
34. Siddiqui AA, Dewitt JM, Strongin A, et al. Outcomes of EUS-guided drainage of debris-containing pancreatic pseudocysts by using combined endoprosthesis and a nasocystic drain. *Gastrointest Endosc* 2013; 78: 589–595. doi: [10.1016/j.gie.2013.03.1337](https://doi.org/10.1016/j.gie.2013.03.1337)
35. Lerch MM, Stier A, Wahnschaffe U, Mayerle J. Pancreatic pseudocysts: observation, endoscopic drainage, or resection? *Dtsch Arztebl Int* 2009; 106: 614–621. doi: [10.3238/arztebl.2009.0614](https://doi.org/10.3238/arztebl.2009.0614)
36. Köhler H, Schafmayer A, Lüdtke FE, Lepsien G, Peiper HJ. Surgical treatment of pancreatic pseudocysts. *Br J Surg* 1987; 74: 813–815. doi: [10.1002/bjs.1800740920](https://doi.org/10.1002/bjs.1800740920)
37. Gumaste VV, Pitchumoni CS. Pancreatic pseudocyst. *Gastroenterologist* 1996; 4: 33–43.
38. Bergman S, Melvin WS. Operative and nonoperative management of pancreatic pseudocysts. *Surg Clin North Am* 2007; 87: 1447–1460. doi: [10.1016/j.suc.2007.09.003](https://doi.org/10.1016/j.suc.2007.09.003)
39. Criado E, De Stefano AA, Weiner TM, Jaques PF. Long term results of percutaneous catheter drainage of pancreatic pseudocysts. *Surg Gynecol Obstet* 1992; 175: 293–298.
40. Hamza N, Ammori BJ. Laparoscopic drainage of pancreatic pseudocysts: a methodological approach. *J Gastrointest Surg* 2010; 14: 148–155. doi: [10.1007/s11605-009-1048-7](https://doi.org/10.1007/s11605-009-1048-7)
41. Park AE, Heniford BT. Therapeutic laparoscopy of the pancreas. *Ann Surg* 2002; 236: 149–158.
42. Hindmarsh A, Lewis MP, Rhodes M. Stapled laparoscopic cystgastrostomy: A series with 15 cases. *Surg Endosc* 2005; 19: 143–147. doi: [10.1007/s00464-004-9042-3](https://doi.org/10.1007/s00464-004-9042-3)