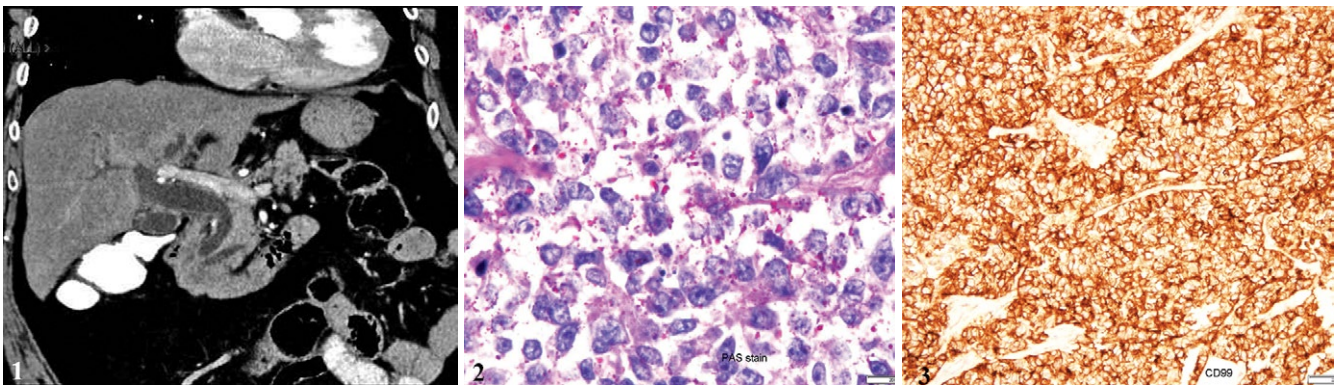


Extraosseous Ewing Sarcoma Arising at the Papilla of Vater

Ilan Kent^{1,4}, Evgeny Edelstein^{2,4}, Olga Levin^{3,4}, Yaron Wiener^{1,4}

1) Department of Surgery, and 2) Department of Pathology, Meir Medical Center, Kfar-Saba; 3) Department of Pathology, Sheba Medical Center, Tel-Hashomer; 4) Sackler Faculty of Medicine, Tel Aviv University, Tel Aviv, Israel



A 72-year-old female developed progressive jaundice. Computerized tomography (CT) showed a dilated common bile duct and main pancreatic duct, without visualizing a definite obstructing mass (Fig. 1). The patient underwent an endoscopic ultrasound, which demonstrated an irregular heterogeneous papillary mass measuring 2.3x1.7 cm at the second part of the duodenum. A pancreaticoduodenectomy (Whipple's procedure) was performed. Macroscopically, gross examination of the duodenal mucosa revealed a tumor in the region of the papilla of Vater, measuring 3x2x1.5 cm. Cytoplasm of the tumor cells contained numerous PAS-positive glycogen granules (PAS positive, abolished with diastase pretreatment, Fig. 2). On immunohistochemistry, the cells showed diffuse membranous positivity for CD99 (Fig. 3). All other stains were negative. The morphological and immunophenotypical characteristics were consistent with a peripheral primitive neuroectodermal tumor (pPNET)/Ewing sarcoma (EWS). The patient denied adjuvant treatment and two months after the operation, she presented with complaints of abdominal pain and diplopia. A CT scan revealed diffusely metastatic disease that included liver and brain metastasis. The patient passed away one week later.

Ewing's sarcoma and peripheral primitive neuroectodermal tumors (pPNET) are part of Ewing's sarcoma family of tumors (ESFTs). These tumors typically arise in bones and soft tissues and have a characteristic translocation in the EWSR1 gene located at 22q12 [1]. Although very rare, there have been reports of ESFTs emerging in the gastrointestinal tract, genitourinary tract, adrenal glands, pancreas, and paravertebral areas [2].

Nearly all ESFTs strongly express CD99, a cell surface glycoprotein encoded by the MIC2 gene [3, 4]. In cases where genetic testing is lacking, diagnosis is heavily based on

immunohistochemistry and positive staining for CD99 [5]. Positive expression of vimentin, S100 and NSE are also useful, but not as specific. Evaluation of negative markers is also essential to distinguish ESFTs from other soft tissue tumors.

This is the first report of EWS/pPNET arising in the duodenal papilla. Despite the rarity of this tumor, it is important to include it in the differential diagnosis due to its aggressive behavior.

Corresponding author: Ilan Kent, ilankent@post.tau.ac.il

Conflicts of interest: None to declare.

REFERENCES

- Carvajal R, Meyers P. Ewing's sarcoma and primitive neuroectodermal family of tumors. *Hematol Oncol Clin North Am* 2005;19:501–525. doi:[10.1016/j.hoc.2005.03.004](https://doi.org/10.1016/j.hoc.2005.03.004)
- Bernstein M, Kovar H, Paulussen M, et al. Ewing's sarcoma family of tumors: current management. *Oncologist* 2006;11:503–519. doi:[10.1634/theoncologist.11-5-503](https://doi.org/10.1634/theoncologist.11-5-503)
- Delattre O, Zucman J, Melot T, et al. The Ewing family of tumors—a subgroup of small-round-cell tumors defined by specific chimeric transcripts. *N Engl J Med* 1994;331:294–299. doi:[10.1056/NEJM199408043310503](https://doi.org/10.1056/NEJM199408043310503)
- de Alava E, Gerald WL. Molecular biology of the Ewing's sarcoma/primitive neuroectodermal tumor family. *J Clin Oncol* 2000;18:204–213. doi:[10.1200/JCO.2000.18.1.204](https://doi.org/10.1200/JCO.2000.18.1.204)
- Kim SK, Park YK. Ewing sarcoma: a chronicle of molecular pathogenesis. *Hum Pathol* 2016;55:91–100. doi:[10.1016/j.humpath.2016.05.008](https://doi.org/10.1016/j.humpath.2016.05.008)