

A potential impact of *Helicobacter pylori* infection on minimal hepatic encephalopathy pathobiology

To the Editor,

In their prospective clinical trial, Schulz et al. concluded that the amount of ammonia produced by *Helicobacter pylori* infection (*Hp*-I) does not influence ammonia serum levels and is not associated with an increased prevalence of minimal hepatic encephalopathy (MHE) in patients with liver cirrhosis (LC). Therefore, an additional benefit of *Hp* eradication in the treatment of HE in LC patients is unlikely to occur [1].

Apart from ammonia, recent considerations [2, 3] postulated that *Hp* may be involved in the pathophysiology of the post-HE persistent cognitive impairment in cirrhotic patients, related with sequelae such as falls, fractures or motor vehicle accidents, by several additional mechanisms. *Helicobacter pylori* may be involved in the pathophysiology of the cirrhosis-related cognitive impairment by releasing proinflammatory and vasoactive substances, involved, through blood-brain-barrier (BBB) disruption, in a number of vascular disorders including mild cognitive impairment (MCI), a prodromal phase of Alzheimer's disease (AD), which can lead to long-term neurologic deficits [4-6].

Specifically, inflammatory mediators (e.g., cytokines and chemokines induced by *Hp*-I) and oxidative stress have been implicated in inducing BBB disruption. *Helicobacter pylori* could indirectly affect the brain through the release of numerous cytokines such as the tumor necrosis factor (TNF)-alpha, acting at a distance; TNF-alpha is involved in BBB disruption through a mechanism involving matrix metalloproteinases upregulation. In addition, the *Hp*-induced cytotoxin VacA exhibits chemotactic activities to the bone marrow-derived mast cells (BMDMCs) and induces BMDMCs to produce proinflammatory cytokines which disturb the BBB [7, 8]. Mast cell degranulation is able to secrete these potent mediators which could orchestrate neuroinflammation and affect the BBB integrity, thereby playing a role in neuropathies. The "cross-talk" between mast cells, lymphocytes, neurons and

glia constitutes a neuroimmune axis implicated in a range of neurodegenerative diseases with an inflammatory and/or autoimmune component [8]. Blood-brain-barrier disruption could play an important role in promoting the entry of immune cells (autoreactive effector CD4+ and CD8+ T cells) infiltrations and pathogens into the brain resulting in brain pathologies. In this regard, activated monocytes (possibly infected with *Hp* due to defective autophagy resulting in *Hp* replication in autophagic vesicles) might also enter the brain due to BBB disruption (Trojan horse theory), contributing to cirrhosis-related brain pathologies [2, 5, 9].

Helicobacter pylori may be further involved in the pathophysiology of the cirrhosis-related cognitive impairment by promoting platelet-leukocyte aggregation proposed to play pathophysiologic roles in MCI, AD and liver fibrosis; producing reactive oxygen metabolites involved in AD pathophysiology and complications of cirrhosis; causing the development of cross mimicry between endothelial and *Hp* antigens; increasing homocysteine, a risk factor for chronic liver disease-related abnormalities of endothelial function, MCI, dementia and AD, implicated in endothelial damage and neurodegeneration via oxidative injury in these diseases; or influencing the apoptotic process, an important form of cell death in AD and cirrhosis [2, 5].

Therefore, eradication therapy of *Hp*-positive cirrhotic patients might have a beneficial effect on MHE [10]. Since there is lack of relative literature showing evidence to support the aforementioned considerations, large-scale studies are required to elucidate these fields.

Jannis Kountouras, Stergios A. Polyzos, Emmanuel Gavalas, Marina Boziki, Panagiotis Katsinelos, Christos Zeglinas, Elizabeth Vardaka, Constantinos Kountouras, Ioannis Venizelos, Sotiris Anastasiadis, Georgia Deretzi

Department of Medicine, Second Medical Clinic, Aristotle University of Thessaloniki, Ippokratation Hospital, Thessaloniki, Greece

Correspondence: Jannis Kountouras, jannis@auth.gr

Conflicts of interest: No conflicts to declare.

DOI: <http://dx.doi.org/10.15403/jgld.2014.1121.253.pyl>

REFERENCES

- Schulz C, Schütte K, Reisener N, Voss J, Malfertheiner P. Prevalence of *Helicobacter pylori* infection in patients with minimal hepatic encephalopathy. *J Gastrointest Liver Dis* 2016; 25: 191-195. doi: [10.15403/jgld.2014.1121.252.hpy](https://doi.org/10.15403/jgld.2014.1121.252.hpy)
- Kountouras J, Zavos C, Deretzi G, et al. *Helicobacter pylori* induced cognitive dysfunction might be associated with falls and fractures in cirrhosis. *Hepatology* 2013; 57: 1284. doi: [10.1002/hep.25926](https://doi.org/10.1002/hep.25926)
- Kountouras J, Zavos C, Polyzos SA, Katsinelos P, Deretzi G. Association between cirrhosis and *Helicobacter pylori*-related brain pathologies. *Eur J Gastroenterol Hepatol* 2015; 27: 183. doi: [10.1097/MEG.0000000000000248](https://doi.org/10.1097/MEG.0000000000000248)
- Kountouras J, Zavos C, Deretzi G, et al. Impact of *Helicobacter pylori* on chronic hepatitis C-related cognitive dysfunction. *J Neuroimmunol* 2011; 233: 254-256. doi: [10.1016/j.jneuroim.2010.09.022](https://doi.org/10.1016/j.jneuroim.2010.09.022)
- Kountouras J, Tsolaki M, Boziki M, et al. Association between *Helicobacter pylori* infection and mild cognitive impairment. *Eur J Neurol* 2007; 14: 976-982. doi: [10.1111/j.1468-1331.2007.01827.x](https://doi.org/10.1111/j.1468-1331.2007.01827.x)
- Kountouras J, Zavos C, Deretzi G. *Helicobacter pylori* might contribute to persistent cognitive impairment after resolution of overt hepatic encephalopathy. *Clin Gastroenterol Hepatol* 2011; 9: 624-625. doi: [10.1016/j.cgh.2011.02.011](https://doi.org/10.1016/j.cgh.2011.02.011)
- Kountouras J. *Helicobacter pylori*: an intruder involved in conspiring glaucomatous neuropathy. *Br J Ophthalmol* 2009; 93: 1413-1415. doi: [10.1136/bjo.2009.159046](https://doi.org/10.1136/bjo.2009.159046)
- Kountouras J, Deretzi G, Zavos C, et al. *Helicobacter pylori* infection may trigger Guillain-Barré syndrome, Fisher syndrome and Bickerstaff brainstem encephalitis. *J Neurol Sci* 2011; 305: 167-168. doi: [10.1016/j.jns.2011.03.015](https://doi.org/10.1016/j.jns.2011.03.015)
- Franceschi F, Gasbarrini A, Polyzos SA, Kountouras J. Extragastric diseases and *Helicobacter pylori*. *Helicobacter* 2015; 20 Suppl 1: 40-46. doi: [10.1111/hel.12256](https://doi.org/10.1111/hel.12256)
- Kountouras J, Polyzos SA, Deretzi G. *Helicobacter pylori* associated with obstructive sleep apnea might contribute to sleep, cognition, and driving performance disturbances in patients with cirrhosis. *Clin Gastroenterol Hepatol* 2015; 13: 154. doi: [10.1016/j.cgh.2015.02.009](https://doi.org/10.1016/j.cgh.2015.02.009)

Reply,

We are thankful to Kountouras and colleagues who commented on our article "Prevalence of *Helicobacter pylori* infection in patients with minimal hepatic encephalopathy" that was published in JGLD in June 2016 [1].

In our prospective clinical study we did not detect a significant statistical correlation of blood ammonia levels and (minimal) hepatic encephalopathy with serologically detected *H. pylori* infection.

Changes in the intestinal microbiota composition in patients with liver cirrhosis have been detected recently [2, 3], and current established therapies for hepatic encephalopathy mainly aim at a reduction of ammonia production from the gastrointestinal tract. The role of *H. pylori* as part of the microbiota or as a modifier of gut microbiota composition has not been thoroughly investigated so far in well designed prospective clinical trials [4]. In contrast, published clinical studies are inconsistent in their results as we have shown in a recent systematic review [5].

Certainly, many factors apart from ammonia are involved in the pathogenesis of hepatic encephalopathy. These include amongst others, mercaptans, aromatic amino acids, short and medium chain fatty acids, endogenous benzodiazepines and proinflammatory cytokines [6]. *H. pylori* might be involved in the pathogenesis also via these systemic mediators.

The thoughtful comments of Kountouras and colleagues with referral to the most recent hypotheses on the role of *H. pylori* infection and related mechanisms on cognitive impairment in patients with liver cirrhosis are so far not supported by prospective data. We appreciate these annotations to our paper which might encourage future research in this challenging field.

In this context an important next step will be to differentiate the metabolic functions of individual bacteria within the microbiota community. The production of urease and the induction of proinflammatory responses resulting in the release of cytokines and other mediators is not a unique characteristic of *H. pylori* but also of other gut bacteria, e.g. *Proteus* spp., *Ureaplasma urealyticum*, *Nocardia* and certain enteric bacteria as *Morganella* spp., *Klebsiella* spp. and *Serratia* spp [7]. Other factors with impact on systemic ammonia levels include portosystemic shunts, hepatocyte dysfunction and the effect of pharmacological interventions on the intestinal microbiome as a whole. It must be kept in mind that studies analyzing the effects of *H. pylori* eradication on the cognitive function in patients with liver cirrhosis are influenced by the systemic effects of antibiotic therapy.

We agree and strongly support the request for adequately designed large-scale prospective clinical studies to elucidate the underlying mechanisms of hepatic encephalopathy. Such studies will clarify if *H. pylori* does truly contribute to the pathogenesis of hepatic encephalopathy.

Christian Schulz, Kerstin Schütte, Peter Malfertheiner on behalf of all authors

Department of Gastroenterology, Hepatology and Infectious Diseases, Otto-von-Guericke University, Magdeburg, Germany

Correspondence: Christian Schulz, christian.schulz@med.ovgu.de

Conflicts of interest: No conflicts to declare.

DOI: <http://dx.doi.org/10.15403/jgld.2014.1121.253.ply>

REFERENCES

- Schulz C, Schütte K, Reisener N, Voss J, Malfertheiner P. Prevalence of *Helicobacter pylori* infection in patients with minimal hepatic encephalopathy. *J Gastrointest Liver Dis* 2016; 25: 191-195. doi: [10.15403/jgld.2014.1121.252.hpy](https://doi.org/10.15403/jgld.2014.1121.252.hpy)
- Bajaj JS, Heuman DM, Hylemon PB, et al. Altered profile of human gut microbiome is associated with cirrhosis and its complications. *J Hepatol* 2014; 60: 940-947. doi: [10.1016/j.jhep.2013.12.019](https://doi.org/10.1016/j.jhep.2013.12.019)
- Bajaj JS, Betrapally NS, Hylemon PB, et al. Salivary microbiota reflects changes in gut microbiota in cirrhosis with hepatic encephalopathy. *Hepatology* 2015; 62: 1260-1271. doi: [10.1002/hep.27819](https://doi.org/10.1002/hep.27819)
- Zullo A, Ridola L, De Francesco V, Hassan C. *Helicobacter pylori* eradication for hepatic encephalopathy treatment: the ideal study is still lacking!. *J Clin Gastroenterol* 2015; 49: 88-89. doi: [10.1097/MCG.000000000000139](https://doi.org/10.1097/MCG.000000000000139)

5. Schulz C, Schütte K, Malfertheiner P, Does H. pylori eradication therapy benefit patients with hepatic encephalopathy?: systematic review. *J Clin Gastroenterol* 2014; 48: 491-499. doi: [10.1097/MCG.000000000000108](https://doi.org/10.1097/MCG.000000000000108)
6. Häussinger D, Schliess F. Pathogenetic mechanisms of hepatic encephalopathy. *Gut* 2008; 57: 1156-1165. doi: [10.1136/gut.2007.122176](https://doi.org/10.1136/gut.2007.122176)
7. Kosikowska P, Berlicki Ł. Urease inhibitors as potential drugs for gastric and urinary tract infections: a patent review. *Expert Opin Ther Pat* 2011; 21: 945-957. doi: [10.1517/13543776.2011.574615](https://doi.org/10.1517/13543776.2011.574615)

Feasibility of volumetric laser endomicroscopy in Barrett’s esophagus with dysplasia and in post-ablation surveillance

To the Editor,

We present our initial experience with Volumetric Laser Endomicroscopy (VLE) by NvisionVLE™ Imaging System (Cambridge, MA) in patients with Barrett’s esophagus (BE). VLE is a second generation optical coherence tomography which provides high resolution (10 micron) real time images to evaluate esophageal tissue microstructure up to 3mm depth [1]. This has a potential role in identifying abnormal areas which are otherwise not visible on white light endoscopy (WLE) and also in identifying buried BE in post-ablation surveillance of patients with BE. Normal esophageal squamous mucosa is seen by VLE as a layered horizontal architecture without glands in the epithelium [2]. In intestinal metaplasia, VLE shows loss of layered architecture with no surface pits, crypts or glands. Dysplasia is suspected if there is complete effacement with surface intensity greater than subsurface intensity or if there is partial effacement with greater than five atypical glands. Homogeneous scattering is suggestive of high-grade dysplasia (HGD) or cancer. Our aim was to evaluate the feasibility of this technique to obtain high resolution images of gastric cardia, gastroesophageal junction and esophagus in a series of patients with BE at our institution.

Patients presenting for initial treatment of BE with dysplasia or post-ablation surveillance were recruited. Patients with esophageal varices and diseases preventing full distention of VLE catheter balloon (esophageal masses, strictures, eosinophilic esophagitis and bleeding diathesis) were excluded. In total, nine patients underwent upper endoscopy with WLE followed by passage of the VLE catheter through a GIF-1T endoscope (Table I). The catheter was positioned and the balloon was inflated to obtain cross-sectional images of 6cm length. High resolution images of gastric cardia, gastroesophageal junction and esophagus were obtained in all patients. VLE was technically feasible in all patients. There were no complications. Tissue acquisition, either targeted or random, with large capacity biopsy forceps was performed based on the endoscopists’ discretion. VLE images were correlated with histological diagnosis. Among the nine patients that were studied, two presented for initial therapy of whom one had low grade dysplasia (LGD) and the other had intra-mucosal carcinoma (IMC). Of the seven patients presenting for post-ablation surveillance, initial diagnosis was IMC in one, HGD in four and LGD in two patients. In the patient with IMC, VLE in

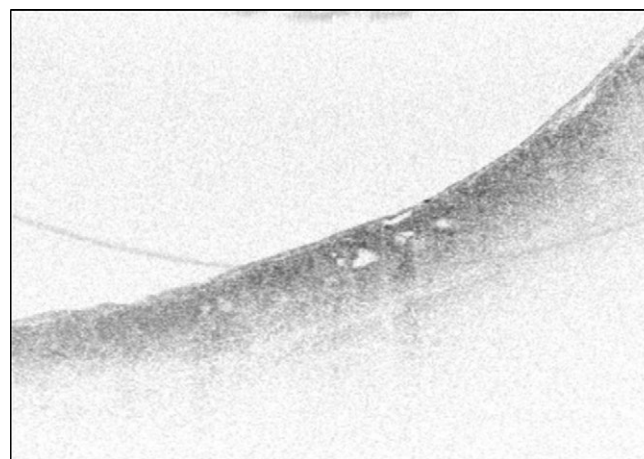


Fig. 1. (Patient 1) Homogeneous scattering suggestive of esophageal cancer.

Table I. Summary of patients’ prior and current diagnosis and treatments

Patient #	Prior diagnosis	Prior treatment	Tissue acquisition	Treatment	VLE results	Pathology results
1	IMC	None	Targeted biopsy & guided EMR	EMR	IMC	IMC
2	LGD	RFA	Random biopsy	None	Buried Barrett’s	No metaplasia
3	LGD	RFA	Random biopsy	None	Buried Barrett’s	No metaplasia
4	HGD	RFA	Random biopsy	RFA	Normal	No metaplasia
5	HGD	RFA, EMR, PDT	Random biopsy	None	Buried Barrett’s	No metaplasia
6	LGD	None	None	RFA	Dysplasia	N/A
7	HGD	RFA	Random biopsy	None	Normal	No metaplasia
8	IMC	RFA, EMR	Targeted biopsy	RFA	Normal	IMC
9	HGD	RFA	Random biopsy	None	Buried Barrett’s	No metaplasia

EMR: endoscopic mucosal resection; HGD: high grade dysplasia; IMC: intramucosal cancer; LGD: low grade dysplasia; PDT: photodynamic therapy; RFA: radiofrequency ablation.

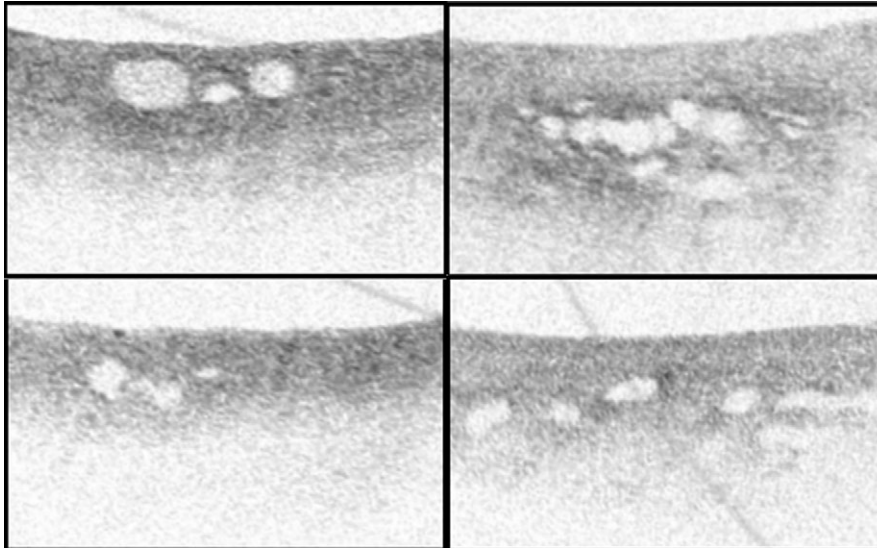


Fig. 2. (Clockwise from top left: Patient 2, Patient 3, Patient 5, Patient 9). Glands in the epithelium suggesting buried Barrett's esophagus.

conjunction with WLE findings guided a targeted Endoscopic Mucosal Resection (EMR) and histology confirmed IMC (Fig. 1). In a case of LGD, VLE identified suspicious areas which correlated with histology findings. In four cases presenting for post-ablation surveillance, VLE detected features indicative of buried BE but the forceps biopsies did not show any metaplasia (Fig. 2). In the remaining three cases, normal VLE appearance correlated with histological findings.

We conclude that VLE is a feasible technique which can be used for cross-sectional real time imaging during upper endoscopy. When VLE based targeted biopsies were performed in BE with dysplasia, VLE images were consistent with histological diagnosis. In addition, VLE has a potential role in post-ablation surveillance of BE as it detected areas of BE that were not identified on WLE and four quadrant surveillance biopsies.

Tanmayee Benjamin, Sampurna Shakya, Prashanthi Nagavenkata Thota

Center of Excellence for Barrett's Esophagus, Digestive Disease Institute, Cleveland Clinic, Cleveland, OH, USA

Correspondence: Prashanthi N. Thota, thotap@ccf.org

Conflicts of interest: The authors declare no conflict of interest.

Acknowledgement: Grant Support: Prashanthi N. Thota, MD-Ninepoint Medical, Cambridge, MA, USA.

DOI: <http://dx.doi.org/10.15403/jgld.2014.1121.253.brt>

REFERENCES

1. Vakoc BJ, Shishko M, Yun SH, et al. Comprehensive esophageal microscopy by using optical frequency-domain imaging (with video). *Gastrointest Endosc* 2007; 65: 898-905.
2. Trindade AJ, George BJ, Berkowitz J, Sejpal DV, Mckinley MJ. Volumetric laser endomicroscopy can target neoplasia not detected by conventional endoscopic measures in long segment Barrett's esophagus. *Endosc Int Open* 2016; 4: E318-E322. doi: [10.1055/s-0042-101409](https://doi.org/10.1055/s-0042-101409)

Occurrence of hepatocellular carcinoma 13 years after successful antiviral treatment for HCV infection

To the Editor,

The optimal follow-up duration in patients with HCV-related chronic liver disease (CLD) achieving sustained virological response has not been yet clearly defined [1]. We describe here the case of a patient with minimal CLD, developing cirrhosis and hepatocellular carcinoma (HCC) 13 years after successful antiviral treatment.

On January 2002, a 40-year-old man discovered he was anti-HCV positive (HCV 2a/2c, HCV RNA 450,000 IU/mL). The alanine aminotransferase (ALT) levels and ultrasound were normal. Body mass index (BMI) was 22 kg/m². The HBsAg, HbcAb, anti-HIV, autoantibodies were negative. Blood cell count, serum lipids and ferritin were normal. The patient was teetotaler. Liver biopsy showed minimal degree of liver damage (Metavir A1F0).

On June 2002, PEG-Interferon alfa-2a 180 mcg/week plus ribavirin 800 mg/day were started. HCV RNA was undetectable at week 4, week 12 and week 24 of treatment, and therapy was stopped in December 2002. During the following two years, the patient underwent biochemical and virological check-ups every six months and ultrasound yearly, with normal results and persistent HCV RNA negativity. Then he was lost for the follow up.

In January 2015, the patient complained of pain in the right upper abdominal quadrant, progressive abdominal swelling and fatigue. The ALT was x1.5 normal values (NV), gamma glutamyl transferase (GGT) x15 NV, alkaline phosphatase (ALP) x5 NV, total bilirubin 4.2 mg/dL, conjugated bilirubin 2.2 mg/dL, white blood cells (WBC) 3,000/mm³, platelet (PLT) count 40,000/mm³, Hb 9.4 g/dL, mean corpuscular volume (MCV) 104 fl., albumin 2.2 g/dL, ferritin 900 ng/mL, normal transferrin saturation. Alpha fetoprotein serum was 3,000 ng/mL. HCV RNA, HBsAg, HbcAb, anti-HIV, and other autoantibodies

were negative. Liver scan, contrast-enhanced CT scan and MRI showed the features of cirrhosis, with multifocal HCC. Upper digestive endoscopy showed esophageal varices F2 and severe portal hypertensive gastropathy, the lower digestive tract endoscopy was normal. Symptomatic treatment was performed [2]. On March 2016 the patient died.

The risk of HCC in patients with HCV clearance has been recently reported [3]. We previously reported the occurrence of HCC in a “healthy” HCV carrier, thus suggesting that HCV should be regarded as an intrinsically oncogenic virus [4].

We are not able to explain the rapid progression to cirrhosis and HCC in a subject with persistent HCV RNA negativity and pre-treatment minimal liver damage, in the absence of other possible causes of cirrhosis. This patient was teetotaler and this point was repeatedly confirmed by his relatives. Thus, high MCV and GGT might have been due to the cirrhosis and to HCC per se, rather than to alcohol abuse. No increase in BMI was reported during the past 12 years. We could only suggest that, in this case, HCV continued to replicate below the limits of detectability of the current methods, or alternatively, that HCV indefinitely might persist within the hepatocytes, similarly to the HBV.

In our opinion, this case presents a great relevance. IFN is an “indirect” antiviral agent, showing immune modulating, antifibrotic and antiproliferative properties. By contrast, new direct antiviral agents (DAAs) only inhibit HCV replication, not exerting the IFN effects on the host. Thus, one should predict that the long term incidence of HCC in non-cirrhotic patients treated with DAAs will be decreased less than in patients with IFN-induced SVR.

Claudio Puoti, Gaetano Lanzetta, Emilio Scotti
INI Research Institute and Clinics, Grottaferrata, Rome, Italy

Correspondence: Claudio Puoti, puoti@epatologia.org

Conflicts of interest: No conflict to declare.

DOI: <http://dx.doi.org/10.15403/jgld.2014.1121.253.hcv>

REFERENCES

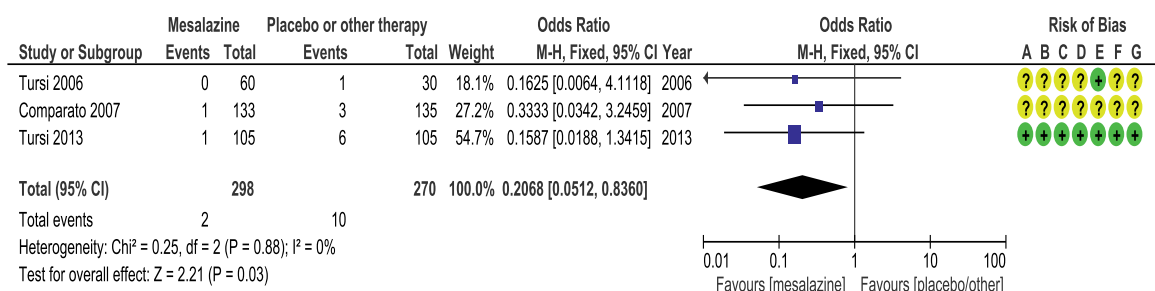
1. European Association for Study of Liver. EASL Recommendations on Treatment of Hepatitis C 2015. *J Hepatol* 2015; 63: 199-236. doi: [10.1016/j.jhep.2015.03.025](https://doi.org/10.1016/j.jhep.2015.03.025)
2. Bruix J, Sherman M. Management of hepatocellular carcinoma: an update. *Hepatology* 2011; 53: 1020-1022. doi: [10.1002/hep.24199](https://doi.org/10.1002/hep.24199)
3. El-Serag HB, Kanwal F, Richardson P, Kramer J. Risk of hepatocellular carcinoma after sustained virological response in veterans with hepatitis C virus infection. *Hepatology* 2016; 64: 136-137. doi: [10.1002/hep.28535](https://doi.org/10.1002/hep.28535)
4. Puoti C, Bellis L, Martellino F, et al. Occurrence of hepatocellular carcinoma in an apparently ‘healthy’ HCV patient. *Eur J Gastroenterol Hepatol* 2005; 17: 1263-1264.

Mesalazine in preventing acute diverticulitis occurrence: a meta-analysis of randomized, controlled trials

To the Editor,

Diverticular disease (DD) of the colon is one of the commonest diseases in the western world, and its prevalence is also increasing the developing world [1, 2]. A large debate is currently ongoing regarding the best treatment for those patients. Mesalazine, thanks to its anti-inflammatory effect, has been actively investigated both in open-label and in double-blind fashion. However, the use of mesalazine in the treatment of DD should still be clarified.

With respect to the efficacy of mesalazine to prevent diverticulitis recurrence, a recent meta-analysis performed by Khan et al. [3] showed that mesalazine was ineffective in preventing acute diverticulitis recurrence. However, these results are confounding for the following two reasons: 1) Published placebo-controlled randomized controlled trials (RCTs) had employed different methods to detect recurrent diverticulitis: only two of them [4, 5] used CT to confirm



Risk of bias legend
 (A) Random sequence generation (selection bias)
 (B) Allocation concealment (selection bias)
 (C) Blinding of participants and personnel (performance bias)
 (D) Blinding of outcome assessment (detection bias)
 (E) Incomplete outcome data (attrition bias)
 (F) Selective reporting (reporting bias)
 (G) Other bias

Fig. 1. Forest plot analyzing the effect of mesalazine in preventing acute diverticulitis occurrence.

Table I. Characteristics of the included studies.

Study	Intervention	Inclusion criteria	Exclusion criteria	Follow-up (months)
Tursi [2]	Mesalazine 800 mg bid vs. mesalazine 800 mg bid + Lactobacillus casei 750 mg a day vs. Lactobacillus casei 750 mg a day for 10 days every month	Recurrent SUDD, diagnosis of diverticular disease with colonoscopy.	Active or recent peptic ulcer, chronic renal insufficiency, allergy to salicylates, and presence of diverticulitis complications.	12
Comparato [3]	Mesalazine 400 mg bid vs. mesalazine 800 mg bid vs. rifaximin 200 mg bid vs. rifaximin 400 mg bid for 10 days every month	Age 18-85 years, endoscopic and/or radiologic evidence of diverticular disease of the left colon, presence of SUDD.	Solitary diverticulum of the colon, signs of diverticulitis, previous colonic surgery, concomitant colonic or extra-colonic cancer, use of antibiotics in the previous 4 weeks, chronic hematological and/or hepatic and/or renal diseases, immunodeficiency, pregnancy or lactation, proven intolerance to rifaximin or mesalazine, a questionable ability to cooperate.	12
Tursi [4]	Mesalazine 800 mg bid vs. Mesalazine 800 mg bid + Lactobacillus casei 750 mg a day vs. Lactobacillus casei 750 for 10 days every month	Patients aged >18 years, diverticulosis showed by colonoscopy, presence of SUDD, free and informed consent, negative pregnancy test, agreement to use a valid contraceptive method for the duration of the study, patients not requiring hospitalization, patients willing and able to provide written informed consent.	Acute diverticulitis, diverticular colitis, active or recent peptic ulcer, chronic renal insufficiency, allergy to salicylates, patients with intended or ascertained pregnancy, lactation, women of child-bearing age not using contraceptives, lactulose-lactitol use, previous use of probiotic, inability to give a valid informed consent, active or previous malignancy, recent history or suspicion of alcohol abuse or drug addiction, use of nonsteroidal anti-inflammatory drugs, inability to give valid written informed consent.	12

SUDD, symptomatic uncomplicated diverticular disease.

diverticulitis recurrence, and they were the only trials showing efficacy of mesalazine; and 2) Inclusion criteria were heterogeneous, since placebo-controlled RCTs enrolled patients with a large variability of the clinical characteristics of the acute diverticulitis attacks. In particular, only one placebo-controlled RCT [5] enrolled patients following the first attack of acute diverticulitis and, again, this was the trial in which mesalazine was effective.

Since the main target of mesalazine is the colonic mucosa, it should be used preferably in patients at the first episode of acute diverticulitis with a low grade of fibrosis in the colonic wall.

However, mesalazine seems to be more effective in controlling symptoms in patients suffering from Symptomatic Uncomplicated Diverticular Disease (SUDD) [6, 7] and could be also effective in preventing diverticulitis occurrence.

As far as we know, there are three RCTs in the literature, which compared mesalazine, irrespective of the associated therapies and dosage regimen, with placebo or any other therapy (fibers, rifaximin, probiotics) in SUDD (Table I) [7-9]. Only one trial was of high quality [7]. Globally, diverticulitis occurred in 2 out of 298 [0.7%] patients in the mesalazine group and in 10 out of 270 [3.7%] patients in the non mesalazine group. Pooled analysis showed a statistically significant difference in favour of the mesalazine group (OR 0.21, 95%CI 0.05-0.83, $p=0.03$) (Fig. 1). Heterogeneity was not statistically significant ($I^2=0\%$, $p<0.88$).

As we wait for new placebo-controlled trials, we suggest that mesalazine needs a correct positioning in the DD treatment. In particular, we claim that a tailored approach is required to obtain tailored results in DD patients. According to our results and Khan's meta-analyses, mesalazine should be used to treat symptoms and prevent diverticulitis occurrence in SUDD,

rather than to prevent diverticulitis recurrence, especially in patients with previous multiple attacks of acute diverticulitis.

Antonio Tursi¹, Marcello Picchio²

1) Gastroenterology Service, ASL BAT, Andria (BT); 2) Division of Surgery, P. Colombo Hospital, Velletri (Rome), Italy

Correspondence: Antonio Tursi, antotursi@tiscali.it

Conflicts of interest: No conflict to declare.

DOI: <http://dx.doi.org/10.15403/jgld.2014.1121.253.msx>

REFERENCES

1. Tursi A, Papa A, Danese S. Review article: the pathophysiology and medical management of diverticulosis and diverticular disease of the colon. *Aliment Pharmacol Ther* 2015; 42: 664-684. doi: [10.1111/apt.13322](https://doi.org/10.1111/apt.13322)
2. Tursi A. Diverticulosis today: unfashionable and still under-researched. *Therap Adv Gastroenterol* 2016; 9: 213-228. doi: [10.1177/1756283X15621228](https://doi.org/10.1177/1756283X15621228)
3. Khan MA, Ali B, Lee WM, Howden CW. Mesalazine does not help prevent acute colonic diverticulitis: a meta-analysis of randomised, placebo-controlled trials. *Am J Gastroenterol* 2016; 111: 579-581. doi: [10.1038/ajg.2016.24](https://doi.org/10.1038/ajg.2016.24)
4. Stollman N, Magowan S, Shanahan F, Quigley EM; DIVA Investigator Group. A randomized controlled study of mesalazine after acute diverticulitis: results of the DIVA trial. *J Clin Gastroenterol* 2013; 47: 621-629. doi: [10.1097/MCG.0b013e31828003f6](https://doi.org/10.1097/MCG.0b013e31828003f6)
5. Parente F, Bargiggia S, Prada A, et al. Intermittent treatment with mesalazine in the prevention of diverticulitis recurrence: a randomised multicentre pilot double-blind placebo-controlled study of 24-month duration. *Int J Colorectal Dis* 2013; 28: 1423-1431. doi: [10.1007/s00384-013-1722-9](https://doi.org/10.1007/s00384-013-1722-9)

6. Kruis W, Meier E, Schumacher M, et al; German SAG-20 Study Group. Randomised clinical trial: mesalazine (Salofalk granules) for uncomplicated diverticular disease of the colon--a placebo-controlled study. *Aliment Pharmacol Ther* 2013; 37: 680-690. doi: [10.1111/apt.12248](https://doi.org/10.1111/apt.12248)
7. Tursi A, Brandimarte G, Elisei W, et al. Randomised clinical trial: mesalazine and/or probiotics in maintaining remission of symptomatic uncomplicated diverticular disease - a double-blind, randomised, placebo-controlled study. *Aliment Pharmacol Ther* 2013; 38: 741-751. doi: [10.1111/apt.12463](https://doi.org/10.1111/apt.12463)
8. Tursi A, Brandimarte G, Giorgetti GM, Elisei W. Mesalazine and/or Lactobacillus casei in preventing recurrence of symptomatic uncomplicated diverticular disease of the colon: a prospective, randomized, open-label study. *J Clin Gastroenterol* 2006; 40: 312-316. doi: [10.1097/01.mcg.0000210092.77296.6d](https://doi.org/10.1097/01.mcg.0000210092.77296.6d)
9. Comparato G, Fanigliuolo L, Cavallaro LG, et al. Prevention of complications and symptomatic recurrences in diverticular disease with mesalazine: a 12-month follow-up. *Dig Dis Sci* 2007; 52: 2934-2941. doi: [10.1007/s10620-007-9766-8](https://doi.org/10.1007/s10620-007-9766-8)

Henoch Schonlein purpura and *Clostridium difficile* infection: a hematologist's point of view

To the Editor,

Henoch Schonlein purpura is a form of immune vasculitis that affects venules of the skin, joints, intestinal mucosa and the kidneys. Deposits of immune complexes containing immunoglobulin A (IgA) can be identified in the circulation, as well as in the wall of the inflamed vessels. The pathophysiology of this disease is not properly understood but several case series have described its appearance after exposure to aspirin, enalapril, cabidopa, as well as other drugs [1, 2]. Cojocariu et al. have described a very interesting case of Henoch Schonlein purpura complicated with *Clostridium difficile* infection [3]. As IgA vasculitis is diagnosed after the intake of various drugs, it is a known fact that it is clearly associated with medication [4, 5]. A biopsy of the duodenum would probably have been useful for the differential diagnosis, in order to identify IgA and C3 complexes and thus perform a complete clinical assessment [6]. Although some have urged categorizing Henoch Schonlein purpura with its cutaneous vasculitis (palpable purpura) (Fig. 1), sufficient characteristic features are often missed. These include IgA deposits and involvement of the joints, intestinal

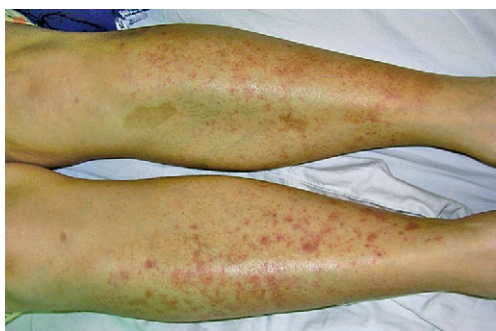

Fig. 1. Clinical aspect of Henoch-Schonlein purpura.

mucosa and kidneys, which means a biopsy is very useful before initiating steroid therapy.

In this patient, we do not see a clear correlation between *Clostridium difficile* infection and Henoch Schonlein purpura because, during the period, the patient was hospitalized and under corticotherapy, thus immunosuppressed, at least in some degree. Therefore, the infection could have been nosocomial and not related to the purpura.

While we are sure that the authors provided the best treatment of the patient, we still consider that in this case there is no clear evidence that the *Clostridium difficile* infection was a complication of immunoglobulin A vasculitis.

Delia Dima, Ciprian Tomuleasa, Mihnea Zdrengea

Department of Hematology, Ion Chiricuta Oncology Institute, Cluj Napoca, Romania

Correspondence: Ciprian Tomuleasa, ciprian.tomuleasa@umfcluj.ro

Conflicts of interest: No conflict to declare.

DOI: <http://dx.doi.org/10.15403/jgld.2014.1121.253.sch>

REFERENCES.

1. Barut K, Sahin S, Kasapcopur O. Pediatric vasculitis. *Curr Opin Rheumatol* 2016; 28: 29-38. doi: [10.1097/BOR.0000000000000236](https://doi.org/10.1097/BOR.0000000000000236)
2. Audemard-Verger A, Pillebout E, Guillevin L, Thervet E, Terrier B. IgA vasculitis (Henoch-Schönlein purpura) in adults: Diagnostic and therapeutic aspects. *Autoimmun Rev* 2015; 14: 579-585. doi: [10.1016/j.autrev.2015.02.003](https://doi.org/10.1016/j.autrev.2015.02.003)
3. Cojocariu C, Stanciu C, Ancuta C, Danciu M, Chiriac S, Trifan A. Immunoglobulin A Vasculitis Complicated with *Clostridium difficile* Infection: a Rare Case Report and Brief Review of the Literature. *J Gastrointest Liver Dis* 2016; 25: 235-238. doi: [10.15403/jgld.2014.1121.252.csd](https://doi.org/10.15403/jgld.2014.1121.252.csd)
4. Santoro D, Stella M, Castellino S. Henoch-Schönlein purpura associated with acetaminophen and codeine. *Clin Nephrol* 2006; 66: 131-134.
5. Escudero A, Lucas E, Vidal JB, et al. Drug-related Henoch-Schönlein Purpura. *Allergol Immunopathol (Madr)* 1996; 24: 22-24.
6. Calvo-Río V, Loricera J, Ortiz-Sanjuán F, et al. Revisiting clinical differences between hypersensitivity vasculitis and Henoch-Schönlein purpura in adults from a defined population. *Clin Exp Rheumatol* 2014; 32(3 Suppl 82): S34-S40.

Reply,

We thank Dr. Dima, Tomuleasa and Zdrengea for their interest and comments on our paper regarding Immunoglobulin A vasculitis (formerly called Henoch-Schonlein purpura) complicated with *Clostridium difficile* infection (CDI) [1]. We entirely agree that the intake of various drugs has been associated with the development of Henoch-Schonlein purpura [2], and that a biopsy of the duodenum is useful for the diagnosis by identifying with immunofluorescence staining the Ig A – immune deposits and C3 complexes in the wall of the small vessels. However, Henoch-Schonlein purpura is mainly a clinical diagnosis, easily made in the presence of skin purpura, but more difficult when the onset is accompanied by gastrointestinal manifestations, without cutaneous purpuric rash [3] as was the case of our patient.

The peculiarity of our case is the development of CDI, an extremely rare complication of Henoch-Schonlein purpura, being, in fact, the second case reported in adults in the literature. We agree with Dima et al. that hospitalization and corticotherapy might have played a key role in the development of CDI. Moreover, as we mentioned in our paper, the patient received antibiotics (amoxicillin) for pharyngitis, prescribed by the primary care physician prior to hospital admission. The use of antibiotic therapy remains the most important risk factor for the development of CDI [4]. The antibiotic therapy together with the intestinal lesions (mucosal ischemia) caused by Henoch-Schonlein purpura and the corticotherapy administered for the treatment of this disease could all have led to changes in gut microbiota and, consequently, to the overgrowth of *Clostridium difficile*, increasing the risk of CDI.

Camelia Cojocariu^{1,2}, Carol Stanciu², Anca Trifan^{1,2}

1) Gr. T. Popa University of Medicine and Pharmacy; 2) St. Spiridon Emergency Hospital, Institute of Gastroenterology and Hepatology Iasi, Romania

Correspondence: Anca Trifan, ancatrifan@yahoo.com

Conflicts of interest: None to declare.

DOI: <http://dx.doi.org/10.15403/jgld.2014.1121.253.coj>

REFERENCES

1. Cojocariu C, Stanciu C, Ancuta C, Danciu M, Chiriac S, Trifan A. Immunoglobulin A Vasculitis Complicated with *Clostridium difficile* Infection: a Rare Case Report and Brief Review of the Literature. *J Gastrointest Liver Dis* 2016; 25: 235-238. doi: [10.15403/jgld.2014.1121.252.csd](https://doi.org/10.15403/jgld.2014.1121.252.csd)
2. Gonzales-Gay MA, Calvino MC, Vazquez-Lopez ME, et al. Implication of upper respiratory tract infections and drugs in the clinical spectrum of Henoch-Schönlein purpura in children. *Clin Exp Rheumatol* 2004; 22: 781-784.
3. Mills JA, Michel BA, Vloch DA, et al. The American College of Rheumatology 1990 criteria for the classification of Henoch-Schönlein purpura. *Arthritis Rheum* 1990; 33: 1114-1121. doi: [10.1002/art.1780330809](https://doi.org/10.1002/art.1780330809)
4. Khanna S, Pardi DS. The growing incidence and severity of *Clostridium difficile* infection in inpatient and outpatient settings. *Expert Rev Gastroenterol Hepatol* 2010; 4: 409-416. doi: [10.1586/egh.10.48](https://doi.org/10.1586/egh.10.48)